



Understanding Chromosome & Gene Disorders

45,X/46,XY

including Y chromosome rearrangements



rarechromo.org

Sources and references

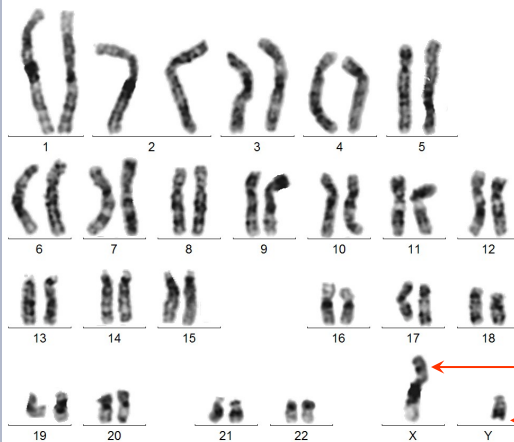
The information in this guide is drawn from the medical literature and from *Unique's* own members. In particular, information is drawn from extensive reviews of people with the 45,X/46,XY diagnosis. The first-named author and publication date are given to allow you to look for the abstracts or original articles on the internet in PubMed (at www.ncbi.nlm.nih.gov/pubmed). If you wish, you can obtain articles from *Unique*. The reviews include:

Hsu 1989;
 Chang 1990;
 Telvi 1999;
 Fernández-García 2000;
 Siffroi 2000;
 Willis 2006;
 Álvarez Nava 2008;
 Layman 2009.

45,X/46,XY, including Y chromosome rearrangements

“ We have managed with the diagnosis very well. The only big issue we had was when we were told that his gender had to be checked, a very difficult time. The main impact I feel is not being able to talk openly about his condition because of the nature of his problems - *parent of a 2-year-old boy*

“ It required a significant adjustment period. What do you say when you discover your reproductive organs are partly male and partly female? Or that it even affected your face? My husband's diabetes has more effect on us now, however - *adult, brought up as male but changed gender to female*



A typical karyotype for a boy or man: all the chromosomes in a cell - including one X chromosome and one Y chromosome

Most people have two sex chromosomes in the cells of their body. Women have two X chromosomes and men have one X chromosome and one Y chromosome. People with 45,X/46,XY have two different types of cell. One contains an X chromosome and a Y chromosome. The other contains a single X chromosome. A sizable number of people with 45,X/46,XY have a variant form where the Y chromosome has an unusual structure. See [45,X/ structurally abnormal Y chromosome](#) [pages 13-15].

The two different cell types, one with a single X, the other with an X and a Y, can be found throughout the body - in the blood, skin, brain, heart, teeth, reproductive organs and so on. The proportion of X cells to XY cells is often different in different organs of the body.

If the entire body contained only XY cells, the result would be a typical man or boy. When some cells only contain an X, the 45,X/46,XY condition arises. The condition has many different names. These include [XY-Turners](#), [mosaic XY/XO](#) and [XO/XY](#). Using the expression 45,X/46,XY is probably best, most nearly accurate, and the least confusing.

The majority of people with 45,X/46,XY are apparently normal men and boys and go unnoticed until puberty or later, if at all. Some, around one in 20, are female and have a form of Turner syndrome - that is, they are more like girls born with a 45,X genetic constitution [karyotype]. One in 20 are born with external reproductive organs that show incomplete male development and may appear as partly masculinised female genitalia. The term [mixed gonadal dysgenesis](#) is sometimes used for this group. 'Gonadal dysgenesis' means inadequate development of the gonad or gonads. New terminology refers to this condition as one of the sex chromosome [Disorders of Sex Development](#) [DSDs].

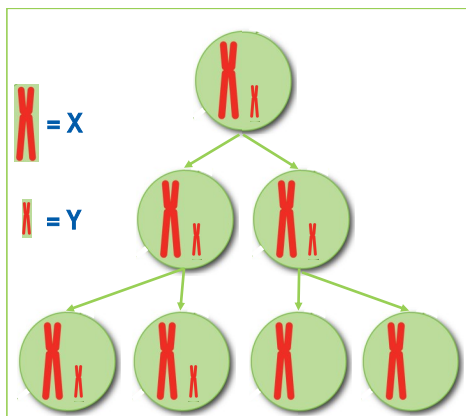
How common is 45,X/46,XY?

Like most errors in the number of chromosomes, this is a rare condition. At birth around 30 babies in every 200,000 have 45,X/46,XY. This is the equivalent of 118 babies a year in the United Kingdom, 650 in the US and 44 in Australia (Chang 1990). However, the large majority of embryos with an abnormal number of chromosomes, including those with 45,X, do not survive to the end of a pregnancy. Most likely, the individuals with this condition who survive to birth have a far less abnormal chromosome presence than those who do not survive. In other words, there is a range of chromosomal anomalies within what we call 45,X/46,XY: the variations are very complex, and the actual result in living individuals is often not a simple picture of having some of their cells with 45 chromosomes [one of which is an X] and the rest with 46 chromosomes [one an X and one a Y]. For ease of understanding, however, we generally use the designation 45,X/46,XY.

How did this happen?

When a baby is made at conception, a single cell is created that contains two copies of each chromosome as well as the sex chromosomes X and Y for a boy or two Xs for a girl. Each cell must then make many copies of itself and of all the chromosomes it contains in order to make the many billions of cells that form during human growth and development. In a normal situation, all the cells in an individual will have 46 chromosomes with one being an X and one a Y or with two Xs. However, sometimes during this complicated copying process, one chromosome can be lost. In 45,X/46,XY, most or all of the Y chromosome is lost in one of the newly-created cells. All the cells then made from this cell will lack the Y chromosome. All the cells created from the cells that haven't lost the Y chromosome will be XY (Telvi 1999).

The 46,XY cells will continue to multiply at the same time as the 45,X cells multiply. The embryo, then the fetus and then the baby will have what is called a 45,X/46,XY constitution. This is called a [mosaic](#) karyotype because, like tiles in mosaic floors or walls, there is more than one type of cell. Sometimes the Y chromosome in the original single cell created at conception has a structural abnormality. It's thought that the structural abnormality occurred first in the Y chromosome, which then became less good at dividing efficiently and so it disappeared, or most of it disappeared from one population of cells, leading to the 45,X cell line.



Words

Specific technical words and phrases are used to describe some of the consequences of a 45,X/46,XY karyotype. You will find some of the key terms below. Over time, some definitions have changed and this means that some people, including doctors and support groups, use terms that are now out of use.

Ambiguous genitalia Abnormal sexual anatomy of a newborn that raises the question about the appropriate sex-of-rearing for the baby. Recognize that the 'ambiguity' is in the eyes of the observer. [See also [Intersex](#)]

Contralateral streak On one side of the body only, a small scar or 'streak' of internal tissue made up mainly of fibrous tissue. It may have a few cells from a very incompletely developed and malfunctioning gonad.

Dygenesis Inadequate [or abnormal] development. As in [Gonadal dysgenesis](#) and [Mixed gonadal dysgenesis](#), below.

Dysgenetic Inadequately [or abnormally] developed. As in [Dysgenetic testes](#), testes that have developed abnormally.

Dysgenetic testis Testis that has developed abnormally and incompletely. If there are two testes, both abnormally developed, the term is [dysgenetic testes](#). The degree of abnormality is very variable and ranges from an organ mainly composed of fibrous tissue with a few tubular structures to a fundamentally normal testis just with small tubules and few germ cells. In the presence of dysgenetic testes, external genitals may be chiefly male or chiefly female, depending on how abnormal the testis function was in utero.

Gonadal ridge The structure that appears in an embryo that at around five weeks begins to give rise to the gonads [ovaries or testes, typically].

Germ cells The cells that give rise to sperm [in a male] or egg cells [in a female].

Gonad The organ that makes sperm [in a male] or egg cells [in a female]. In a male with 46,XY chromosomes, the gonads are testes. In a female with 46,XX chromosomes, the gonads are ovaries. In very early pregnancy, before males and females start to develop differently at about 6-8 weeks, there are no gonads, only a gonadal ridge that looks the same in both sexes.

Gonadal streak A very small scar-like structure, made up mainly of fibrous tissue, where the gonad should have developed. Occasionally the term is used when there are a very few, very poorly developed gonadal cells present.

Gonadal dysgenesis Incomplete [abnormal] development of the gonads during embryonic life.

Intersex Someone whose sex organs [genitalia] and reproductive structures have features normally associated with both males and females.

Mixed gonadal dysgenesis Usually referring to a baby who experienced abnormal [asymmetric] development of the embryonic and fetal gonads, leading to development of so-called ambiguous genitalia.

Müllerian structures The embryonic structures that develop into the female reproductive tract, that is, uterus, vagina and fallopian tubes.

Ovarian stroma Soft tissue in the ovary within which the follicles containing immature eggs develop.

Ovotestis A gonad that contains tissue of both a definite ovary and a definite testis.

Phenotype Appearance and other features resulting from the interaction of the genetic constitution with its environment.

Streak gonad A very small scar-like structure made up mainly of fibrous tissue, where the gonad should have developed.

Testis The organ in the male that produces a major male hormone (testosterone). Plural is **testes**.

Testosterone The male sex hormone secreted by the testes. Testosterone is converted by many male organs into a more powerful male sex hormone, dihydrotestosterone.

What are the main features of 45,X/46,XY?

Most children with 45,X/46,XY are apparently healthy, normal-appearing boys. Many of these boys commonly have no risks or problems from their genetic condition at all.

- At birth around 90 per cent of babies with 45,X/46,XY have normal-appearing external male genitals, five per cent have normal-appearing female genitals and in five per cent the external reproductive organs are neither fully male nor fully female.
- Of the normal-appearing males, most will have two normally functioning testes. But one quarter to one third of them will not. One testis or both may be non-functioning, or one may contain mostly fibrous tissue with a small amount of testicular cells, or on one side there may be a non-functioning complete gonadal streak. If there is no gonadal function, an embryo will develop into a female or at least have external female genitalia. In 45,X/46,XY the sexual differentiation into male is incomplete - mildly, moderately, or severely. Underlying the female: male difference is the presence or absence on the Y chromosome (or, uncommonly, on the cells that appear to have a 45,X composition) of the SRY gene. The proportion of gonadal cells with an SRY gene is important. The SRY gene determines whether an individual baby will become male or female, by setting the scene for the testes to develop in the first place, because they then produce the hormone testosterone. If too small a number of gonadal cells have the SRY gene, this results in the development of dysgenetic gonads.
- Some people with a 45,X/46,XY karyotype have reduced fertility and some are infertile. No judgement can be made about fertility until well after puberty in the apparently normal males.
- People with a 45,X/46,XY karyotype can have any of the medical conditions that are more common among girls with Turner syndrome (who have a 45,X karyotype). These include heart and kidney disorders, autoimmune disorders and being short in height. (Chang 1990; Hashimoto 1997; Reddy 1998; Robinson 1999; Telvi 1999; Quilter 2002; Patsalis 2006; Premi 2009; Tosson 2010)

Is 45,X/46,XY permanent? Can it change?

It is important to realise that when amniocentesis is done - when fluid around the fetus is withdrawn using a syringe with a needle that is pushed through the mother's tummy, through the uterine wall, and into the amniotic sac around the fetus - the cells floating around in this fetal fluid may be genetically abnormal. However, many of these genetic abnormalities in utero are corrected during embryonic and fetal growth and so may not be present or may be much less present when the baby is born. That is, in the very early days after conception, when the baby is made, if there are some cells without the Y chromosome, some of these cells may disappear. But after that, any remaining 45,X cells will give rise to 45,X cells while the 46,XY cells will multiply into XY cells. By the time a baby is born, its 45,X/46,XY make-up is permanent.

How is 45,X/46,XY diagnosed?

45,X/46,XY is diagnosed by examining the chromosomes in a blood sample, a sample of the fluid around the baby in the womb [amniotic fluid] or the developing placenta [chorionic villus sample].

The chromosome test will typically give a result that looks something like this: 45,X[10]/46,XY[90]. This means that 100 cells have been tested. Of the 100 cells, 90 contain 46,XY, the full set of chromosomes for a normal male. The 10 remaining cells only have 45 chromosomes, having lost the Y chromosome. Sometimes the chromosome test gives a result that contains the word **mos**. This is short for **mosaic** and repeats what you already know, that in one individual who developed from a single fertilised egg, there are two populations of cells - also called cell lines - each with a different chromosome make-up.

It's natural to wonder whether having a low proportion of cells without the Y chromosome means that the individual person with 45,X/46,XY will be more mildly affected, or whether having a high proportion of cells without the Y chromosome means they will have more severe effects. This isn't necessarily the case at all.

The reason is mainly that the cells tested are usually from blood or shed from the baby's skin into amniotic fluid. The cells that determine sexual differentiation are in the internal reproductive organs. So the chromosome test gives an overall diagnosis. But it doesn't predict how 45,X/46,XY will affect an individual. (Tosson 2010; Karatza 2009; Premi 2009; Telvi 1999; Papenhausen 1991; Chang 1990)

When is 45,X/46,XY diagnosed?

45,X/46,XY is found most often in men with fertility difficulties. Sometimes it is found in adolescents whose puberty is late or incomplete. It is occasionally found in children who are short for their age and in newborn babies who have unusual genital features, such as an abnormal penis and with testicles that are not in the scrotum at birth. It is also found, usually by chance, when a baby's chromosomes are tested during pregnancy.

This variety of times of diagnosis is reflected among 10 *Unique* members. Four were diagnosed by chance during pregnancy, one following chorionic villus sampling, two after amniocentesis for an older mother and a third after an ultrasound scan due to maternal diabetes. Three babies were identified at birth, two with genital anomalies and one with unspecified birth defects. Three were diagnosed as adults, one following years of gender dysphoria [where a person feels uneasy about their sex-of-rearing], one after fertility investigations revealed azoospermia [no sperm] and one for unspecified reasons.

■ Adult men

One man was found to have 45,X/46,XY when he developed enlarged breasts as an adult (Knudtzon 1987).

■ Men with fertility difficulties

Not all men with 45,X/46,XY have fertility difficulties, but many do. As a result, many men with 45,X/46,XY are identified when their chromosomes are checked as part of investigations requested by a fertility clinic. There can be marked differences between such men. Some are short, others not. Most are in every other way entirely typical men, but they may have only very low sperm counts [oligospermia] or none at all [azoospermia]. In some cases, but not all, their testosterone levels are low when compared to fertile men. Of the men who do produce sperm, some - but not all - have

more sperm with extra or missing chromosomes than is normally seen, although it is not well understood why. Some men will achieve a natural pregnancy with their partner. Others use assisted reproduction. (Koeberl 1995; Newberg 1998; Telvi 1999; Giltay 2000; Dale 2002; Blanco 2003; Alvarez Nava 2006; Layman 2009; *Unique*)

“I’m infertile as a result of the condition. I’m phenotypically normal, so it doesn’t affect my everyday life, but in retrospect, I wish I had known when younger (18?) that I was infertile, so I could have made plans/decisions/etc. I also feel it’s somewhat unfair on my wife in that I married and have gone 10 years without children without knowing I was infertile. If I had been aware of my infertility, we could have planned for children earlier [we’re now in the process of going for sperm donor]. I think my infertility is something she had a right to know about when we married.

■ Adolescents

45,X/46,XY can come to light when boys are investigated for unusually late puberty. Occasionally 45,X/46,XY comes to light when a girl who is late to go into puberty is investigated. Adolescents with 45,X/46,XY may also be unusually short [short stature], although not all are. An adolescent will have hormone tests as well as the chromosome test that reveals the 45,X/46,XY make-up and management will be decided on the results of the hormone tests. (Papadimas 2001; Tosson 2009)

■ Children and babies

45,X/46,XY can come to light when a child is investigated for unusually short height or when a baby boy is investigated for testicles that have not descended into the scrotum (Tosson 2009; *Unique*).

■ At birth

45,X/46,XY is sometimes found at birth when a baby is born whose genitals are apparently incompletely in a little boy or very slightly male-like in a little girl (‘ambiguous genitalia’). A baby boy may have undescended testicles. The urethral opening normally at the end of the penis may be on the underside instead [hypospadias]. The penis may be curved when erect [chordee] and very small. The scrotum may be divided. There may be a vagina as well as male genitals. A baby girl may have an enlarged clitoris. It may be unclear whether the baby is a boy or a girl. 45,X/46,XY can also be found at birth or in the newborn period when a baby is investigated for non-specific developmental or clinical problems, such as floppiness [hypotonia], feeding difficulties or seizures (*Unique*).

“At birth he presented with hypotonia, was lethargic and had a poor sucking reflex. His chromosomes were tested at 3 weeks but the test was repeated at 3 months and the Y monosomy mosaicism was detected – parent of 3-year-old with 45,X/46,XY

■ During pregnancy

When 45,X/46,XY is found during pregnancy, parents want to know how their baby will be affected. 45,X/46,XY can be found when a chorionic villus sample [CVS] is taken or when fluid is drawn off from around the baby [amniocentesis]. A CVS result is normally double-checked by repeating the test on amniotic fluid. Sometimes a mosaic result on CVS is followed by a normal result showing 46,XY on amniocentesis.

A number of large studies of babies diagnosed as 45,X/46,XY during pregnancy have shown that the great majority (90-95 per cent) will have normal-appearing male genitals and be apparently normal baby boys. A much smaller number will have minor genital anomalies such as hypospadias. An even smaller number will have normal female genitals, or normal female genitals with an enlarged clitoris. There is nonetheless a significant risk - around 1:3-4 - that even in normal-appearing males, the cells in the testes will be abnormal.

A pregnancy diagnosis of 45,X/46,XY is usually followed by the offer of a high-level ultrasound scan at 16-22 weeks to examine in detail the heart, kidneys, body and genitals. If necessary, the scan can be repeated to gain greater clarity as the baby grows. (Chang 1990; Hsu 1994; Lazebnik 1996; Huang 2002; Kibar 2009; Layman 2009)

What happens when a baby boy is 45,X/46,XY?

Broadly speaking, there are two groups of boys with 45,X/46,XY: those whose testes do not produce enough testosterone and have very low or negligible sperm counts, and those whose hormone levels are unaffected but may have diminished sperm production.



20 months old

If a baby boy is found to have 45,X/46,XY, he will have an abdominal ultrasound scan and hormone tests. This is because even if the external genitals look entirely normal for a baby boy, the testes may in fact be abnormal. However, most baby boys with normal genitals have normal testes, although their fertility may be reduced. If the scan shows remains of an internal female reproductive system, these can be removed - but they often do not have to be, because most commonly they never cause any problems. Any surgery to correct minor anomalies of the genitals will be planned, such as correction of a curved penis [chordee] and surgery to bring the urethral opening to the end of the penis [hypospadias repair, or urethroplasty]. If the testicles are not already in the scrotum, their position will be checked on the abdominal scan. If the testes are in the inguinal canal and so have started their journey from the abdomen to the scrotum, hormone treatment with human chorionic gonadotrophin is sometimes tried to stimulate testosterone production and

encourage the testicles to descend. If this does not work, the testes can be brought into the scrotum and anchored there in a minor surgical operation known as an orchidopexy. Hormone levels will be checked periodically.

If any surgery is undertaken on the genital area, molecular analysis is likely to be performed on the gonadal tissue because the gonads are strongly influenced by the percentage and distribution of Y-chromosome containing cells.

The baby's heart will be imaged, paying particular attention to the abnormalities that are common in Turner syndrome. Among the hormone and endocrine tests, there will usually be a test for autoimmune thyroid disease.

Growth will be carefully monitored and if it is very slow, doctors will explain the pros and cons of giving growth hormone.

Boys with 45,X/46,XY will then usually have annual endocrinology visits and ultrasound scans. Once a boy with 45,X/46,XY reaches adolescence, he may need hormone treatment with testosterone. (Tosson 2010; Hjerrild 2008; Tho 2007; Richter-Unruh 2004; Canning 1999; Telvi 1999; Hashimoto 1997; Linskens 1992; Chang 1990; Aimakhu 1976; *Unique*)

“For us the actual diagnosis, whilst a shock, was less of an issue than the lack of specific information surrounding it. The diagnosis means very little to us at the moment as he appears to be developing completely normally. The future is less certain – parent of 2-year-old with 45,X/46,X ring Y chromosome

What happens when a baby girl is 45,X/46,XY?

Many baby girls with 45,X/46,XY are brought up as girls with Turner syndrome. For an individual girl, the decisions depend on what doctors find on ultrasound and when they examine the gonads directly. Most typically, two streak gonads are found and a decision will be reached on whether to remove them, as well as any testicle-like structure. If the clitoris is very large, it can be made smaller in a surgical operation known as resection. If any surgery is undertaken on the genital area, molecular analysis is likely to be performed on the gonadal tissue because the gonads are strongly influenced by the percentage and distribution of Y-chromosome containing cells in the gonads.

Your daughter will have the levels of certain hormones checked. The heart will be imaged, paying particular attention to the heart abnormalities that are common in Turner syndrome.

Among the hormone and endocrine tests, there will usually be a test for autoimmune thyroid disease.

Growth will be carefully monitored and if it is very slow, doctors will explain the pros and cons of giving growth hormone.

Girls with 45,X/46,XY will then usually have annual endocrinology visits and ultrasound scans. Once a girl with 45,X/46,XY reaches adolescence, she is likely to need hormone treatment to induce puberty.

Doctors will talk to you and your daughter about her future ability to have children. Everyone with 45,X/46,XY is different, but there is at least one case on record of a woman with 45,X/46,XY having two successful pregnancies. (López 1998; Osipova 1998; Canning 1999; Telvi 1999; Fernández-García 2000; Papadimas 2001; Huang 2002; Landin-Wilhelmsen 2004; Richter-Unruh 2004; Doerr 2005; Patsalis 2005; Álvarez Nava 2006; Franceschini 2006; Hjerrild 2008; Tosson 2010)

What happens when it's unclear if the baby is a boy or a girl?

First, the baby will be checked over very carefully. The examining doctor will probably scan the baby's abdominal area with ultrasound to look for the internal reproductive organs and also to check the kidneys and urinary tract. They will take blood samples to check hormone levels and if necessary to double-check the chromosomes. Doctors may need to look at the gonads using laparoscopy, or a 'key-hole' technique, that causes as little distress to the baby as possible. At the same time, they may need to take a biopsy [tiny sample] of the tissue that the gonads are made of. Information from these samples may help to determine the baby's underlying sex.

Internally, doctors may find streak gonads. They may find one or two gonads that are very inadequate testes, possibly with some ovary-like tubules present - but these children are not 'hermaphrodites', that is, they do not have an ovary and a testis - and this can occur in around 1 in 50 people with 45,X/46,XY. They may find one streak gonad and one immature, dysgenetic or normal testis. They may find an internal vagina, cervix and uterus, although these are usually quite small compared to a normal female.

A decision needs to be made whether to bring up a baby as a girl or boy. The decision rests on the results of hormone tests as well as discussions between doctors and parents, with parents or other people in appropriate support groups, or with a few doctors who specialise in the overall growth and development of children with these conditions. It is occasionally not entirely clear whether the baby, while growing up, will come to see itself as a girl or a boy. On the other hand, when any baby is born, it is never clear whether that baby will grow up as an athlete, musician, bad student, social, pleasant, and so forth. People who have been through the boy: girl decision suggest that any surgery should be delayed until the child can help to decide for themselves. They add that it is important for parents to make a decision but then watch for signs that it was wrong because of gender identity problems. Whichever sex-of-rearing is finally chosen, it is likely that some reconstructive surgery may be chosen.



One child: first raised as a boy [left], who had gender reassignment as an adult [centre] and is now happily married [right].

“ His diagnosis at birth was penoscrotal hypospadias. When his left, undescended gonad was removed, it was a streak ovary, which is why he had a chromosome test. The only big issue we had was when we were told at 10 months that his gender had to be checked, a very difficult time - *Parent of 2-year-old, brought up as a boy*

“ The doctors could not agree upon gender identification or what surgery to perform. The decision was us as his parents and we chose male because he had more male organ tissue which has turned out to be the right decision - *parents of adult man*

What are the signs of Turner syndrome and how are they managed?

Some signs of Turner syndrome can often be found in people with 45,X/46,XY.

■ Growth

Some people with 45,X/46,XY, though certainly not all, are short. Some are short from birth, in others growth is slow in childhood and in the majority there is no growth spurt at puberty. Among *Unique's* members with more than two different cell lines or with a structurally abnormal Y chromosome, 4/6 are unusually short for their family.

There is some evidence that girls with 45,X/46,XY are more consistently short and are shorter than boys with 45,X/46,XY. Their growth rate slows when they are still toddlers if they had both gonads removed in the first year of life. Short height is caused by the loss of a growth gene from the short arm of chromosome Y. Because the Y chromosome is only lost from some cells of the body and not all, girls are typically taller than girls with 'pure' Turner syndrome, that is, girls with a 45,X chromosome make-up.

Giving growth hormone increases height but not all families are prepared to give a daily injection. Giving hormones at puberty limits eventual adult height so families and doctors have to strike a balance between achieving a good adult height and starting puberty.

"His height has upset me but he makes up for it with his infectious cheeky character! He's growing, but slowly along the 9th percentile and is quite a bit smaller than his cousins of the same age. We expect growth hormone will be given but we haven't yet discussed this in depth. Even though he is small, we feel it's not fair on him to go through a daily injection – 2 years old

"I was under the 5th percentile on growth charts until my late teens. As an adult, I am 5' 6" [1.68m] with a 5' 8" [1.73cm] arm span. I'm a little shorter than other family members. One reason that I'm taller is that I wasn't given any hormones until I had stopped growing –adult woman originally assigned male gender

"At 5' 8" [1.73cm], I'm shorter by 3 or 4 inches [7.5-10cm] than both my two brothers and father –adult man diagnosed at fertility clinic

Build is typically stocky. There is a tendency to overweight as adults, with increased incidence of raised body mass index [BMI] at adult height.

"I have the square body habitus 'typical of gonadal dysgenesis'. My weight problem started when I was 25 but I control it by diet – adult man, with three different cell lines and idic Y chromosomes

"I'd say I have a 'stocky' build with a 'shield-like' chest, which sort of agrees with a mild similarity to what I understand some Turner's syndrome girls are like. My weight problem started in my mid-twenties. I am 16 stone [101.7kg], but with work I can maintain 13 stone [83kg], which is more appropriate. I can control my weight, but I definitely find it harder than others. To maintain 13 stone I have to keep a very strict diet and exercise regime. I'm sure other people don't require as much effort – adult man, 33 years

■ Heart abnormalities

Aortic coarctation, where the aorta that takes the blood from the heart to the rest of the body is narrowed. This forces the left side of the heart to pump harder to push blood through the narrowing. Treatment is tailored to the individual child but if necessary the

narrowed section can be surgically removed or made larger. Holes between the lower, pumping chambers of the heart [ventricular septal defects/ VSDs] are also relatively common.

Among *Unique* members, 3/26 were born with a heart defect, including two with aortic coarctation. Two have a structurally abnormal Y chromosome; the other has a normal Y chromosome. Of these, both babies with aortic coarctation had surgical operations to correct the narrowing and have regular cardiology follow-up but are healthy and doing well. A third baby was born with malformed heart valves which cause some blood to flow backwards within the heart but have caused no health problems by the age of 58.

■ **Kidney abnormalities** can occur, including horseshoe kidney [the kidneys are joined by a bridge of tissue] or a missing kidney.

Among *Unique* members, 2/26 reported structural kidney problems but neither had problems with the functioning of the kidneys.

■ Autoimmune diseases including thyroid disease and diabetes. Thyroid disease affects 1/26 *Unique* members and she takes thyroid replacement therapy. None of the 26 *Unique* members has diabetes, but one is mildly insulin resistant and takes metformin.

■ Inflammatory bowel disease can occur but affects none of the *Unique* members.

■ The bones in the hand linking the wrist with the fingers may be short, especially the bone leading to the fifth [little] finger. The nails may be small and underdeveloped.

■ The elbows may be formed in such a way that they are turned in and the lower arms stick out more than usual [cubitus valgus] but this was only noticed in one *Unique* member at the age of 16.

■ The body may be **asymmetric**, with one leg longer than the other.

■ A cystic hygroma may be seen. This is a sac-like structure filled with lymph, most commonly in the head and neck area, often appearing as a soft bulge under the skin. It is usually removed by surgery.

■ A minority will have mild learning difficulties. Autism has been seen in a small minority and Asperger syndrome and obsessive compulsive disorder in others. Among 26 *Unique* members, at least three have a degree of learning difficulty.

[Andrade 2010; Tosson 2010; Tho 2007; Fontenelle 2004; Richter-Unruh 2004; Telvi 1999; Low 1997; Tuck-Muller 1995; Papenhausen 1991; Gantt 1980]

Why are gonads sometimes removed?

Many people with 45,X/46,XY are at risk of developing a tumour [gonadoblastoma] in one or both of their gonads. The actual risk of developing a gonadoblastoma isn't certain, but is believed to be around 15-20 per cent, with the lowest risk in boys and men who look fully male, a somewhat higher risk in those with ambiguous genitals and a risk of above 20 per cent in 45,X/46,XY females. Anyone with this genetic karyotype should be informed of this risk and should be examined regularly if gonadal tissue is left in place. The gonadoblastoma is not itself malignant but 30-40 per cent of people who have one go on to develop a malignant tumour. The gonadoblastoma usually develops around or after puberty, most often in the teens or 20s, but it can develop in very young babies or in adults beyond their 20s.

Since it's hard to monitor internal gonads closely, to prevent the development of a tumour, malfunctioning or non-functioning internal gonads are sometimes removed surgically in babyhood [gonadectomy]. For girls with Turner syndrome and an XY cell line,

it's usual to remove the gonads. However, for boys there is no uniform management plan and some centres offer repeated screening tests during childhood, followed by annual ultrasound scans of the testes from the age of 4 or 5 years and perhaps a testicular biopsy, especially once puberty is complete. If no evidence of malignancy is found, the annual ultrasound scan continues to the age of 20, when a further biopsy is carried out. If the first biopsy finds any evidence of malignancy, ultrasound scans are performed every three months and the biopsy repeated after a year. If the malignancy persists, the affected testis is either removed surgically or irradiated. If the second biopsy finds no malignant cells, the annual ultrasound screening resumes and a further biopsy is performed after three years. A normal testis is usually left in place.

Among men who are identified during infertility investigations, it's considered reasonable to monitor them closely with regular physical examinations, pelvic ultrasound and endocrine studies and blood tests for tumour markers.

A possible gonadoblastoma gene lies on the Y chromosome near the point where the short and long arms meet [the pericentromeric region], acting as a cancer-promoting gene in the context of a dysgenetic gonad. (Layman 2009; Brant 2006; Peña-Alonso 2005; Huang 2002; Atkins 2000; Gravholt 2000; Müller 1999; Telvi 1999; Hsu 1994; Nagafuchi 1992; Chang 1990)

Can people with 45,X/46,XY have children?

No judgement can be made until puberty about fertility in the apparently normal males but whether male or female, some people with 45,X/46,XY have reduced fertility and some are not themselves able to have children. Having said that, one woman with idic Y had two children naturally. (Landin-Wilhelmsen 2004; Álvarez Nava 2008)

Other diagnoses

More than two different cell lines

In some cases there are more cell lines, in addition to the cell line with a single X chromosome and the cell line with XY. Typically, these may contain more Y chromosomes – 47,XYY, for example – or more X chromosomes – 47,XXY, for example. These additional cell lines mean that other aspects of development will be influenced by these cell populations. For example, boys with only 47,XYY chromosomes tend to be unusually tall for their family. A boy with 45,X/47,XYY/46,XY chromosomes might be expected neither to be especially short nor especially tall.

45,X/ structurally abnormal Y chromosome

About half of people with 45,X/46,XY have a structurally abnormal Y chromosome. Part of the Y chromosome can be missing and there can be an extra copy of another part. Overall, the effects are generally unpredictable, regardless of the form of the Y chromosome. The effects are believed to depend on multiple factors: the instability of the abnormal Y chromosome, leading to a higher proportion of 45,X cells, the level of mosaicism in the gonads and other tissues, the 45,X cell line, the extent of the missing parts of the Y chromosome and to a lesser extent the extra parts. In particular, the presence or absence of the sex-determining SRY region is a key determinant. Not uncommonly there are more than two cell lines and this complicates the picture. Due to this multiplicity, interpreting a diagnosis of 45,X/ with a structurally abnormal Y chromosome is particularly challenging.

However, most often it seems that an apparently normal male baby develops, although there is a wide range of possibilities including female and ambiguous genitalia. Females may be more common than among those with an 45,X/46,XY diagnosis. As with 45,X/46,XY, no judgement can be made until puberty about fertility in the apparently normal males. Ambiguous genitalia are more common when the breakpoint is in the short arm.

Every chromosome has a long arm, called **q** and a short arm, called **p**, joined at a point called the centromere.

Certain features of Turner syndrome will also develop and people with this diagnosis appear to be at risk for developmental delay.

(Layman 2009; Ravel 2009; Willis 2006; Robinson 1999; Teraoka 1998; Tuck-Muller 1995; Hsu 1994; Daniel 1980)

45,X/ with structurally abnormal Y chromosome: different types

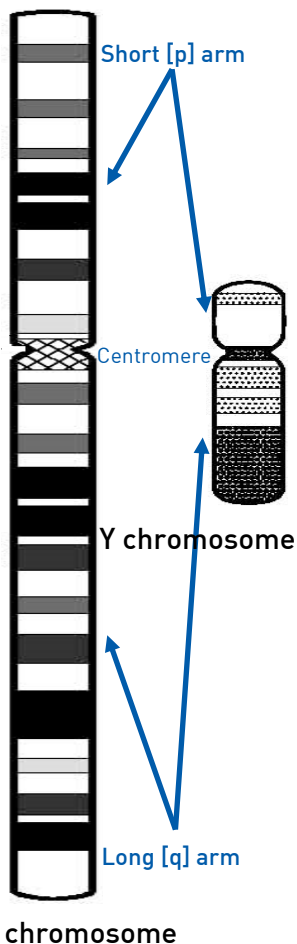
The most common structurally abnormal Y chromosome occurring together with a 45,X cell line is a so-called **dicentric** Y or **isodicentric** Y chromosome. A dicentric Y chromosome is made up of two parts of the chromosome, each containing a centromere and fused end-to-end. In a karyotype, dicentric is shortened to dic. An isodicentric Y chromosome is similar to a dicentric chromosome but the two parts of the Y chromosome are mirror images of each other. Isodicentric is shortened to idic. Sometimes there is a third cell line with a complete extra Y chromosome. In this case the karyotype will read something like 45,X/46,X,dic(Y)/47,XXX.

The typical outcome of pregnancy is an apparently normal baby boy, but there is a slightly higher proportion of baby girls than in 45,X/46,XY. If ultrasound is normal, then the most likely outcome is an apparently normal male baby. The outcome of pregnancy is not related to the proportions of different cell lines. Otherwise, features are broadly speaking the same as for 45,X/46,XY, with a possible risk of growth deficiency, developmental delay and infertility. (Daniel 1980; Tuck-Muller 1995; Teraoka 1998; Huang 2002; Willis 2006)

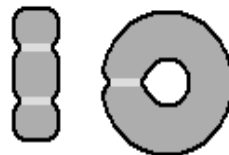
“ It’s early days. We are less likely to leave him with others as he is easily distressed. Obviously we hope this will have as little impact as possible for his development and future so we are optimistic for a bright future - parent of boy, 22 months

■ 45,X/46,idic(Yq) or idic(Yp)

Sometimes the dicentric Y chromosome consists of two copies of the long [q] arm, with two copies of a piece of the short [p] arm. This arrangement can be called idic(Yq), dic(Yq) or i(Yq).



Sometimes the dicentric Y chromosome consists of two copies of the short [p] arm, with two copies of a piece of the long [q] arm. This arrangement can be called idic(Yp), dic(Yp) or i(Yp). The full range of outcomes – female, male and uncertain – can occur. The belief that the vast majority of people with this diagnosis are females may result from skewed data (Valetto 2004; Willis 2006).



Dicentric and ring chromosomes

— centromere
 — genetic material

■ 45,X/46,XYq-

Parts of the long arm of the Y chromosome can be missing. These are shown as Yq-. When the AZF (azoospermia factor) regions on the long arm known as AZFa, AZFb and AZFc are missing, there is an association with infertility. 10-20 per cent of normal men with an apparently normal Y chromosome and infertility actually carry Yq microdeletions. (Patsalis 1998; Siffroi 2000; Álvarez Nava 2006; Álvarez Nava 2008)

■ Ring Y

Sometimes each end of the Y chromosome has been lost and the two broken ends have joined to form a ring. This is known as r(Y). When both testes are descended, the most common effects are on height and sperm production. Men can be anything from unusually short to normal height. Sperm production can range from absent to less severely compromised. Heart and kidney problems are relatively common and germ cell tumours [gonadoblastoma] need to be screened for (Layman 2009).

Behaviour

No clear behavioural pattern is discernible. In fact, behaviour can never really be predicted in anyone. Some people with 45,X/46,XY have behaviour that is indistinguishable from others with typical chromosomes, while others have temper outbursts, a level of obsessive behaviour, anxiety or even severely challenging behaviour. An autism spectrum disorder has been diagnosed in 6/12 *Unique* members. In one child the aggressive behaviour became so hard to handle that his family sought residential care for him. He was unpredictable and one minute could be sharing a joke, the next hitting, biting, kicking and being verbally abusive; he was not calmed by medication. It is not known whether the behaviour difficulties are linked to the sex chromosome anomaly.

“ Usually a happy boy but is prone to horrific temper tantrums, outbursts of swearing and aggression – 12 years

“ Autism causes him to be very anxious and controlling. He is calmer when he knows what is happening throughout the day – 13 years

“ Being assertive is very difficult and my brain reads everything it sees, making it hard to pay attention – *original gender assignment male, reassignment as adult to female.*

“ Immature. Challenging behaviour includes awkward and indecisive, lack of concentration, temperamental possibly due to a sense of inadequacy or inferiority – *male adult with structurally abnormal Y chromosome*

Inform Network Support



Understanding Chromosome & Gene Disorders

Rare Chromosome Disorder Support Group,

The Stables, Station Rd West, Oxted, Surrey. RH8 9EE

Tel: +44(0)1883 723356

info@rarechromo.org | www.rarechromo.org

Turner Syndrome Support Society (UK)

13 Simpson Court, 11 South Avenue, Clydebank Business Park

Clydebank, Scotland G81 2NR

Tel +44(0)141 952 806 | Helpline 0845 2307520 | www.tss.org.uk

xyTurners

info@xyxo.org

Box 5166, Laurel, MD 20726, USA

Facebook

www.facebook.com

There are a number of Turner syndrome Facebook groups.

Join Unique for family links, information and support.

Unique is a charity without government funding, existing entirely on donations and grants. If you can please make a donation via our website at

www.rarechromo.org/donate Please help us to help you!

Unique lists other organisations' message boards and websites to help families looking for information. This does not imply that we endorse their content or have any responsibility for it.

This guide is not a substitute for personal medical advice. Families should consult a medically qualified clinician in all matters relating to genetic diagnosis, management and health. The information is believed to be the best available at the time of publication. It was compiled by *Unique* and reviewed by Dr William G Reiner, Professor of Pediatric Urology and Child and Adolescent Psychiatry, University of Oklahoma, USA and by Professor Maj Hultén BSc PhD MD FRCPATH, Professor of Reproductive Genetics, University of Warwick, UK.

Version 1.0 (PM) 2011

Version 1.1 (SW) 2014

Version 1.11 (AP)

Copyright © Unique 2024