

Support and Information



Rare Chromosome Disorder Support Group,
G1, The Stables, Station Road West, Oxted, Surrey RH8 9EE, United Kingdom
Tel/Fax: +44(0)1883 723356
info@rarechromo.org | www.rarechromo.org

Join Unique for family links, information and support.

Unique is a charity without government funding, existing entirely on donations and grants. If you can, please make a donation via our website at www.rarechromo.org Please help us to help you!

Chromosome 20 and beyond is a Facebook community for anyone affected by a disorder of chromosome 20
www.facebook.com/groups/507113779406575

Unique lists external message boards and websites in order to be helpful to families looking for information and support. This does not imply that we endorse their content or have any responsibility for it.

This information guide is not a substitute for personal medical advice. Families should consult a medically qualified clinician in all matters relating to genetic diagnosis, management and health. Information on genetic changes is a very fast-moving field and while the information in this guide is believed to be the best available at the time of publication, some facts may later change. Unique does its best to keep abreast of changing information and to review its published guides as needed. The guide was compiled by Unique and reviewed by Dr Jaime Garcia-Heras, Director of Cytogenetics, Center for Medical Genetics, Houston, Texas, US 2007, and by Professor Maj Hultén BSc PhD MD FRCPath, Professor of Reproductive Genetics, University of Warwick, UK 2008. (PM)

Copyright © Unique 2008

Rare Chromosome Disorder Support Group Charity Number 1110661
Registered in England and Wales Company Number 5460413



20p deletions

rarechromo.org

Deletions from chromosome 20p

A chromosome 20p deletion is a rare genetic condition caused by the loss of material from one of the body's 46 chromosomes. The material has been lost from the short arm (the top part in the diagram on the next page) of chromosome 20.

Chromosomes are the structures in the nucleus of the body's cells that carry the genetic information that controls development and function. In total every human individual normally has 46 chromosomes. Of these, two are a pair of sex chromosomes, XX (a pair of X chromosomes) in females and XY (one X chromosome and one Y chromosome) in males. The remaining 44 chromosomes are grouped in pairs. One chromosome from each pair is inherited from the mother while the other one is inherited from the father. Each chromosome has a short arm (called p) and a long arm (called q).

Chromosome 20 is one of the smallest chromosomes in man. At present it is known to contain 737 genes out of the total of 20,000 to 25,000 genes in the human genome.

You can't see chromosomes with the naked eye, but if you stain them and magnify their image enough - about 850 times - you can see that each one has a distinctive pattern of light and dark bands. The diagram on the next page shows the bands of chromosome 20. These bands are numbered outwards starting from the point where the short and long arms meet (the **centromere**). A low number, as in p11 in the short arm, is close to the centromere. Regions closer to the centromere are called **proximal**. A higher number, as in p13, is closer to the end of the chromosome. Regions closer to the end of the chromosome are called **distal**. The tips of the chromosomes are called **telomeres**. The areas close to the tips are the **subtelomeric** regions.

Under the microscope, the missing chromosome material (deletion) can usually be identified if it is large enough. Sometimes, however, the deletion is so tiny that the chromosomes look normal under a microscope. This type of deletion is called a **microdeletion** and the loss can only be revealed by special techniques such as FISH or microarrays (array-CGH).

Your geneticist or genetic counsellor will tell you more about how much chromosome material has been lost from the chromosome with the deletion. You will almost certainly be given a shorthand ISCN 2005 code, called a **karyotype**, for your child's chromosome make-up, describing the points where the short arm of chromosome 20 has broken and re-joined or you will be given the results of your child's molecular analysis. Comparing your child's results with others, both from the medical literature and within *Unique*, can help to build up a general picture of what to expect. But there will still be differences, sometimes quite marked, between your child and others with apparently similar deletions. These differences can be due to minute differences in the size of the deletions, to the genes your child has on other chromosomes and to his or her environment from conception onwards, which act together to make him or her into an individual.

Behaviour One child was diagnosed with autism at four years, another with Asperger syndrome at nine years, suggesting the possibility of a specific difficulty with social communication.

How did this happen?

A blood test to check both parents' chromosomes is needed to find out why the 20p deletion occurred. Some 20p deletions occur when both parents have normal chromosomes. The term geneticists use for this is *de novo* (*dn*). De novo 20p deletions are thought to be caused by a change that occurred when the parents' sperm or egg cells were formed or possibly just after fertilisation. We know that chromosomes must break and rejoin in quite a complex process when egg and sperm cells are formed but this only occasionally leads to problems. This is part of a natural process of inheritance and as a parent there is nothing you could have done to change it. Children from all parts of the world and from all types of background have chromosome 20p deletions. No environmental, dietary or lifestyle factors are known to cause them. So there is nothing you did before you were pregnant or during pregnancy that caused this to occur and there is nothing you could have done to prevent it.

Other 20p deletions are the result of a rearrangement in one parent's chromosomes. This is usually a rearrangement known as a balanced translocation in which material has swapped places between chromosomes. As no genetically relevant material has been lost or gained, the parent usually has no clinical or developmental problems, although they may have difficulties with fertility or childbearing. Balanced translocations involving one or more chromosomes are not rare: one person in 500 has one, making a total world population of over 13 million balanced translocation carriers.

One individual occasionally has two cell types, one with normal chromosomes and one with a rearrangement. This is known as **mosaicism**. If a parent has a mosaicism (normal cells and cells with the same abnormal rearrangement as the child), such a parent is most often more mildly affected than the child, and may not be affected at all. Occasionally exactly the same deletion is found in one parent as in the child. The parent may be affected too, sometimes more mildly than their child. Sometimes the parent has the same deletion as the child but has no developmental, learning, medical or behaviour problems. When this happens, a geneticist will usually decide that the 20p deletion is not the cause of the child's difficulties.

Can it happen again?

When both parents have normal chromosomes, it is unlikely that they will have another child with a 20p deletion. When one parent has a rearrangement of their chromosomes or has mosaicism, however, the risk of having another affected child is increased. If the same deletion is present in the parent and the child, the risk of it happening again in each future pregnancy can be as high as 50 per cent.

In future pregnancies, higher-risk families will be offered prenatal testing to study the chromosomes of the coming baby by chorionic villus sampling, amniocentesis or both, and high-level ultrasound screening to monitor growth and identify any anomalies. In a family where one member has already been diagnosed with a 20p deletion, these tests will show whether the pregnancy is affected or not.

centromere (Garcia-Heras 2005; Michaelis 1999; *Unique*). For this reason it is difficult to anticipate the likely effects of a deletion from this area. The recorded deletions, which are different from each other, are 20p11.22-p11.23, 20p11.2, and 20p11.21-p11.23. The following are some of the clinically significant features:

Abnormalities in growth Babies whose deleted 20p comes from their mother may be unusually long and large and grow into tall adults. By contrast, babies whose deleted 20p comes from their father may be unusually small. This suggestion is supported by evidence that children who inherit the two chromosome 20s from their mother (and none from their father) have had prenatal growth failure, have been very short at birth and continued in the smallest three per cent of the population for height (Salafsky 2001; Chudoba 1999).

Constipation Severe constipation occurred in one child with a deletion between 20p11.22 and 20p11.23. It was caused by Hirschsprung's disease, the lack of nerves in part of the bowel, with absence of bowel movements so that the faeces (poo) are not pushed through to the rectum. The same condition was seen in a child in whom this region of both chromosome 20s was inherited from the father. These observations suggest that at least one normal copy of this region is needed on the chromosome 20 inherited from the mother, otherwise Hirschsprung's disease may develop. Hirschsprung's disease is present from birth (babies often do not pass meconium) and is corrected by surgically removing the nerveless segment of the bowel.

Developmental delay It is likely that children will show a degree of developmental delay and may need educational support. One child appeared to develop normally until he was 13 months old, but his speech later regressed. Another child was late to reach baby milestones such as sitting and first walked at 26 months; he also showed delay in using and controlling his hands and was late to acquire and understand speech.

Unusual facial features These children have shown subtly unusual facial features. A nine-year-old boy had a short rectangular forehead, a flat midface, a short upturned nose, downslanting eyes with tiny skin folds across the inner corners, a somewhat pouting lower lip and a forward-jutting lower jaw. A newborn baby boy had mildly abnormal features - prominent occiput (back of the head), sloping forehead, skin folds across the inner corner of both eyes, a small nose with a flat nasal bridge, a left ear pit, sticking out ears and a receding lower jaw.

Hands and feet Soft and fleshy hands, small toes and a wide gap between the big and second toes have been described.

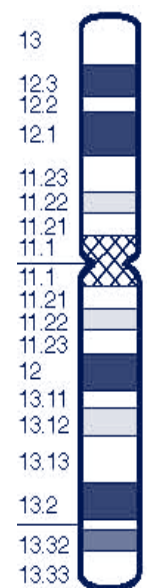
Other medical concerns The number of babies and children with a proximal 20p deletion is too small to establish a consistent pattern of medical concerns. The disorders listed here have affected one baby or child only. **Panhypopituitarism**, the deficiency of all the hormones normally released by the front part of the pituitary gland. These hormones regulate many of the body's natural endocrine processes including stress, growth and reproduction. Treatment is by a paediatric endocrinologist. Congenital (at birth) **4th cranial nerve palsy** causing double vision; treatment is not usually needed, but a child is monitored for signs of amblyopia (lazy eye). **Mild hearing loss** in the left ear at 3 years of age. **Posterior urethral valves** causing a blockage in the tube that leads from the bladder to the penis. Treatment first involves dealing with the symptoms by draining urine through a catheter and then removing the parts of the valve that are causing the blockage.

Sources and references

The information in this leaflet is drawn partly from published medical research papers. We have focused on articles describing people with a 'pure' 20p deletion, without the involvement of other chromosome material that is likely to contribute to the effects, and on articles that include a review of 20p deletions. The first-named author and publication date are given to allow you to look for the abstracts or original articles on the internet in PubMed (<http://www.ncbi.nlm.gov/pubmed/>). If you wish, you can obtain abstracts and articles from *Unique*.

The leaflet also draws on *Unique's* database. When this leaflet was written, *Unique* had seventeen members with a deletion of 20p, of whom five had a pure deletion of 20p. (Ravnan 2006; Adeyinka 2005; Garcia-Heras 2005; Roberts 2004; Sauter 2003; Baker 2002; Laufer-Cahana 2002; Leprêtre 2001; Krantz 1999; Michaelis 1999; Michaelis 1997; Li 1996; Fryns 1992; Teebi 1992; Shohat 1991; Anad 1990; Legius 1990; Schnittger 1989; Kiss and Osztovcics 1988; Silengo 1988; Vianna-Morgante 1987; Byrne 1986; Garcia-Cruz 1985; Kalousek 1976)

Subtelomeric deletions



Approximate site of *subtelomeric deletions*

It has recently become apparent that among young and older children (and adults as well), microdeletions of the distal end of chromosome 20p are relatively common. A molecular cytogenetic test such as FISH or a new molecular test called array-CGH is required to identify this loss of material from distal 20p. These deletions are among the seven most common abnormalities detected on chromosomes by FISH (Ravnan 2006).

In a few cases, the tiny amount of chromosome material lost is not the cause of the medical problems of the child because one healthy parent has the same deletion. These cases are called a **familial variant** and can be passed from parent to child. In other instances, the 20p deletion appears to cause developmental delay with or without additional medical problems. These cases can also be passed from parent to child.

At the moment the only way to differentiate between a familial variant and a deletion that will affect development is to find a family member with a 20p deletion who has normal development. It is not possible yet to identify a familial variant just by examining the chromosome with a 20p deletion.

People with a 20p subtelomeric deletion are likely to have different breakpoints in the chromosome. There isn't enough information about the effects of these differences in breakpoints yet. So far there are 17 known individuals with these deletions.

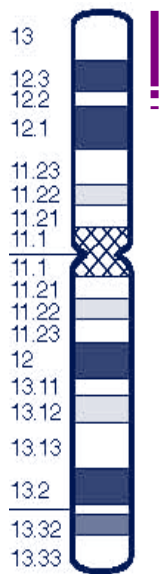
The most common effects of a subtelomeric 20p deletion seem to be:

- A degree of developmental delay
- A degree of growth delay, possibly following normal growth rate in the womb and a normal size and weight at birth.
- A degree of difficulty with learning, so that additional support is needed at school or special schooling is required.
- Some unusual head and facial features. These may include microcephaly (a small head), a long face, deep set eyes that may slant slightly upwards, a small mouth with a short groove between the nose and mouth, a prominent or high forehead, an overfolded outer edge of the ear, large earlobes and coarse hair. At birth the fontanelle (soft spot) on top of the head may be large.

Other features occasionally described are a reduced growth rate with abnormal development of the kidneys, seizures during childhood, delayed eruption of permanent teeth, hearing loss, small hands, flat feet, hypotonia (low muscle tone), difficulties in behaviour, especially with concentration and the development of social skills and a moderate degree of learning disability (Ravnan 2006; Adeyinka 2005; Roberts 2004; Baker 2002; *Unique*).

Quote “ At 13, she is a healthy and well-developed teenager. She still gets one or two ear infections a year but otherwise takes no medicines. Due to a missing auditory canal, she can't locate sound but otherwise accommodates well with her good ear. Her mobility skills are normal for her age and her expressive speech is in advance of her understanding. She started reading when she was eight or nine and can read pre-school books but doesn't enjoy them particularly. She has a statement of special educational need and attends a special school – 20p13 deletion

Single case reports of other deletions from 20p12.2 or 20p12.3 to the end of the chromosome



Approximate site of deletions from 20p12.2 or 20p12.3

There are only four published reports of children with a deletion between band 20p12.2 or p12.3 and the end of the short arm. When so few cases are published, it is not helpful to make generalisations. Reports of the cases therefore follow individually.

A boy with a deletion from 20p12.2

A 16-year-old boy was born at term after a normal delivery with a low birth weight.

Head and face Long head from front to back (dolichocephaly). Some slightly unusual facial features such as a prominent and wide forehead, widely spaced eyes, a wide nasal bridge, a prominent lower jaw and large chin.

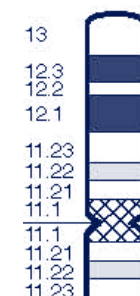lower heart chambers); atrial septal defect (a hole between the two upper heart chambers); aortic stenosis (obstruction to blood flow from the left ventricle to the aorta); and coarctation of the aorta (narrowing of the vessel that takes the blood from the heart to the rest of the body)

- Posterior embryotoxon in the eye or other eye abnormalities. The posterior embryotoxon does not affect vision and is identifiable as a thin line seen at the edge of the iris when the eye is examined under high magnification with a lighted microscope. Other abnormalities of the front part of the eye are also seen. The outlook for eyesight is good despite these changes
- Typical head and facial features. These include a prominent forehead, deep-set eyes that are quite widely spaced (hypertelorism), a pointed chin, a straight or saddle nose with a low bridge and bulbous tip, and low-set or malformed ears. The face has the appearance of an inverted triangle
- Butterfly vertebrae: the vertebrae are cleft, especially in the thoracic (chest) region of the spine, so on an x-ray they look like flying butterflies. This has no effect on a child's development or mobility. There may be other vertebral defects including hemivertebrae (incomplete development of one side of the vertebra, resulting in a wedge shape) or spina bifida occulta (abnormal development of the bones of the spine, seen on x-ray. Nerves may be involved when associated with visible skin changes or a hairy patch, and there may be rib anomalies
- Kidney abnormalities or evidence of kidney disease: anatomical defects such as a single kidney, a kidney in the wrong place, small kidneys, multiple cysts or mis-shapen kidneys

Other less frequent features

- Pancreas. Thirty to 40 per cent of children have pancreatic insufficiency, that is, they do not produce enough of the enzymes that help fat to be absorbed
- Bleeding within the brain
- Developmental delay. Mild delays in gross motor skills, in each case severely affected by liver or congenital heart disease. Mild learning disability
- Delayed puberty and a high-pitched voice
- Hands and limbs: extra crease in fingers; radioulnar synostosis (fusion of the bones of the forearm near the wrist, limiting certain movements)
- Early fusion of the bony plates of the skull (craniosynostosis), macrocephaly (large head).

Proximal deletions of 20p



Approximate site of proximal deletions

There are reports of just three babies and children with a deletion between the jagged I (Alagille syndrome) gene and the

Support for families affected by Alagille syndrome

A support group exists at www.alagille.org. Information is also fairly widely available, from the American Liver Foundation at www.liverfoundation.org and from the Children's Liver Disease Foundation at www.childliverdisease.org.

The information that follows is a brief summary aimed at families with a child with a deletion including the Jagged 1 gene but extending beyond it.

Laboratory Diagnosis

Large deletions that include the *JAG1* gene can be identified in about three to four per cent of patients by a chromosome test. Smaller so-called microdeletions may be detected by FISH using a *JAG1* probe. The smallest deletions of just part or the whole *JAG1* gene are more readily detectable with additional molecular methods such as microarrays. If the FISH test or another molecular method identifies a deletion at 20p12, both parents should be tested to establish whether either carries the same deletion. If either parent does so, there is a chance of mild or barely noticeable clinical signs, and the parent should have a thorough examination.

Current molecular methods can reveal mutations (including deletions) of the *JAG1* gene in 60 to 70 per cent of people with a clinical diagnosis even when the chromosomes look normal under the microscope. With more rigorous screening, detection can be as high as 94 per cent (Warthen 2006).

Main clinical features

The clinical features of Alagille syndrome are highly variable, even between affected members of the same family. The severity can range from unnoticeable subclinical effects to life-threatening disease.

- Prolonged neonatal jaundice (yellowish skin colour) caused by a build-up of bile in the blood
- Severe itching (pruritus), usually developing between the ages of three months and three years
- Xanthomas - white/yellowish bumps under the skin resulting from fat deposits, often seen in elbow and knee creases and at nappy/diaper line. More prevalent during early school years
- Growth delay starting before or after birth. Small for gestational age (birth weight less than 10th percentile) in 16 per cent of babies. Growth delay (length and weight below the 5th percentile during the first three years of life) is even more common
- Cholestasis (obstruction of bile flow out of the liver)
- Too few bile ducts
- Liver disease often presents in the first three months of life and ranges from mild cholestasis, jaundice and itchy skin, to progressive liver failure. Unfortunately, at present it is not possible to predict which newborn babies will develop progressive liver failure
- Heart condition at birth. Mostly a narrowing (stenosis) of the peripheral pulmonary artery and its branches but sometimes complex cardiac abnormalities. The most common complex heart defect is tetralogy of Fallot, in which blood is diverted through a hole between the two lower heart chambers to the aorta, reducing circulation to the lungs. An audible heart murmur in 97 per cent of patients. Other occasional heart defects include a ventricular septal defect (a hole between the two

Bones A spinal curvature (kyphoscoliosis), some butterfly-shaped vertebrae, underdeveloped lower (12th) ribs and a small pelvis.

Heart Diagnosis at one year of age of tetralogy of Fallot, a complex heart condition involving both a hole between the lower pumping chambers of the heart and an obstruction just below the valve in the artery that leads to the lungs. Blue (deoxygenated) blood cannot easily get to the lungs to pick up oxygen and some of it flows through the hole into the other pumping chamber from where it is pumped around the body. Children with tetralogy of Fallot need a surgical operation and in this case the boy died shortly after surgery. This occurred more than twenty years ago and survival has improved dramatically over recent decades. If there are no other risk factors, more than 95 per cent of babies with tetralogy of Fallot nowadays successfully undergo surgery in the first year of life.

Hands Unusual with low-set thumbs, tubular-shaped bones in the fingers and an outward curve of the little (5th) fingers.

Growth and development Global developmental delay. Moderate learning disability. Severe behaviour difficulties.

Seizures Started at 40 days of age, controlled with medication. Seizures stopped by the age of seven years.

Chromosome studies A study in blood (from a vein) showed a deletion of 20p12.2->pter. The studies on his mother, brothers and sisters were normal. The father was not tested.

Reference Garcia-Cruz; Annales de Génétique 28 (4) pages 231-234 (1985).

Two children with a mosaic constitution consisting of cells with a 20p12.2 deletion and cells with normal chromosomes

I A boy aged 3 years 7 months was born at term after a normal pregnancy and delivery weighing 7lb 13oz (3.55kg), with a length of 20 inches (51cm) and a head circumference of 14 inches (35cm). According to the standard growth charts for the United States his weight was in the 25th-50th percentile, his length in the 50th percentile and his head circumference in the 25th percentile (all normal). The baby was noticed to move less during pregnancy than expected. He has no particular problems as a newborn.

Head and face Long face, flat nasal bridge, thin lips, high forehead and prominent, slightly deep-set ears.

Eyes and eyesight Hyperopia (long sight) with convergent squint (strabismus).

Growth and development Delay of gross motor skills with sitting at 20 months, crawling at 21 months and walking with support at 30 months. He had learning difficulties and markedly delayed speech. He did not enjoy physical contact, rarely met his parents' eyes and was diagnosed with autism at the age of 3 years 7 months. He was restless, unable to concentrate and lacked interest in playing with toys or other children. At eight months, he developed myoclonic epilepsy of early childhood. Myoclonic epilepsy of early childhood (Dravet syndrome) is a severe seizure disorder that usually starts during the first year of life in a previously healthy child. The seizures are very resistant to treatment and the first episode is typically triggered by a fever or hyperthermia (overheating). Over time children show a progressive cognitive disability and a slowing in development. There are often neurological problems such as

clumsiness and poor or absent motor co-ordination (ataxia) and behavioural problems (such as autism and hyperactivity). It is possible to treat the seizures with medication in some children. However, even when the seizures respond to treatment intellectual functioning and development remain impaired, sometimes significantly so. Preventing seizures involves carefully avoiding fevers and overheating. Learning ability usually stabilises later but remains below normal.

Chromosome studies A study in blood showed a mosaicism of normal cells (total of 123) and cells with a deletion of 20p12.2 (10 cells). Parental studies were not possible. **Reference** Sauter; American Journal of Medical Genetics 120A pages 533-536 (2003).

2 An 8-year-old girl was born small for dates at 39 weeks of pregnancy, weighing just 3lb 13oz (1.73kg). Apgar scores (measures of wellbeing) of 5 at one minute and 8 at five minutes showed that her condition at birth was not good.

Head and face High, bossed forehead, long face with deep-set eyes, broad and flattened nasal bridge, low-set ears, low hairline at the back of the head. On reflection, these features were considered reminiscent of Alagille syndrome (see pages 7-9).

Eyes and eyesight She had strabismus (a convergent squint) and nystagmus (involuntary eye movements).

Respiratory system She had frequent upper and lower respiratory infections.

Hands and feet Unusually small. She had overlapping fingers and toes. Her hips, elbows and knees did not have a full range of movement.

Growth and development Her growth as a baby and child was extremely slow. She had general developmental delay. She also had generalised hypotonia (low muscle tone, causing floppiness) and rarely moved spontaneously. At a few weeks of age she started to have intermittent seizures, which decreased and then stopped, leaving her free of treatment by the age of five and a half years. Despite being given growth hormone from the age of two, she was in the lowest three per cent of the population for height and weight at the age of seven.

Chromosome studies Two studies from blood samples gave normal results. However, a study from a skin biopsy showed mosaicism (two distinct cell lines with different chromosome make-up). There were seven cells with a 20p deletion involving the 20p12.2 band and 13 cells with normal chromosomes. Both parents had normal chromosomes.

Reference Fryns; Annales de Génétique 35 (4) pages 234-236 (1992)

A boy with a 20p13p12.3 deletion

A boy was born just before his due date at 38 weeks. His Apgar scores (measures of wellbeing) after birth were high (10/10 at one and 5 minutes) but he was noted to be floppy, with low muscle tone (hypotonic). He became breathless and sweaty when breastfeeding but fed better by bottle after 15 days. At birth he had a small penis with a mild degree of hypospadias, where the hole for urine is displaced to the underside of the end of the penis, and he also had club feet. At the age of eight months a doctors' examination revealed these features:

Slightly abnormal facial features High forehead, abnormally formed low-set ears, downslanting eyes, skin folds across the inner corner of both eyes, apparently wide-set eyes, small nose with a bulbous tip, low nasal bridge, a nose with wide and upturned

nostrils, long groove between the nose and upper lip, thin upper lip and a small chin. **Respiratory system** A history of runny nose plus repeated upper respiratory tract and ear infections.

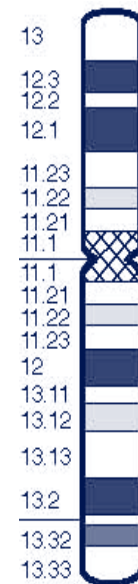Growth and development Hypotonia (low muscle tone). Small body size. Moderate developmental delay, sitting at 12 months, walking at 30 months and speaking his first word at eight months. At the age of eight years he was still a small and thin child although his parents, brothers and sisters were of normal stature. Despite this, his growth hormone levels were normal. He had language delay and while his performance IQ was higher than his verbal IQ, his overall IQ score was 53. He had a short attention span and was moderately hyperactive and aggressive with others.

Other findings Hearing, eyesight and kidneys were normal. At six years of age the boy's flat feet were corrected surgically because of pain.

Chromosome studies A study in blood showed a deletion of 20p with breakpoints at 20p13 and 20p12.3. The parents had normal chromosomes so the deletion in this child was considered a *de novo* event.

Reference Leprêtre; Cytogenetics and Cell Genetics 94 pages 142-146 (2001).

Alagille syndrome (AGS)



Approximate site of deletions causing Alagille syndrome

This is a clinically complex disorder that can affect many organ systems of the body to a widely variable degree, particularly the liver, heart, eyes, face and the bones. Alagille syndrome was also known in the past as arteriohepatic dysplasia, syndromic bile duct paucity or Alagille-Watson syndrome.

Cause

Alagille syndrome is caused by a deletion that results in the loss of a gene known as Jagged1 (*JAG1*) between 20p12.1 and 20p11.23 or by mutations of that gene. Both mechanisms cause an inadequate production of the Jagged1 protein which is found on the surface of certain cells and is important in the fate of cells and development of the liver, heart, skeleton and other body systems.