



Understanding Chromosome & Gene Disorders

# 19p13.3 microdeletions



[rarechromo.org](http://rarechromo.org)

## Sources

The information in this guide is drawn from four sources: the medical literature, the chromosome database Decipher ([www.decipher.sanger.ac.uk](http://www.decipher.sanger.ac.uk)) the Unique members' database and a survey of Unique members. For the published medical literature, the first-named author and publication date are given to allow you to look for the abstracts or original articles on the internet in PubMed ([www.ncbi.nlm.nih.gov/pubmed/](http://www.ncbi.nlm.nih.gov/pubmed/)). If you wish, you can obtain most articles from Unique.

A survey of Unique members was conducted in Winter 2013/2014 (referenced Unique). When this guide was written (Spring 2014), Unique had nine members with a 19p13.3 microdeletion. The nine Unique members range in age from 2-16 years old with two teenage members. There are seventeen people described in the medical literature ranging in age from newborn - 34 years old. The Decipher database lists 22 people with a 19p13.3 microdeletion. Medical information provided by the published literature, and in particular Decipher, does not generally go into as much depth as the Unique member surveys.

## 19p13.3 microdeletion

A 19p13.3 microdeletion is a very rare genetic condition, in which there is a tiny piece of one of the 46 chromosomes missing. In this case, it is from the region known as 19p13.3 on chromosome 19 (see diagram on page 3). As 19p13.3 microdeletions are rare, there is not much information available. This is an emerging syndrome and some people may be more affected by the microdeletion than others.

## Genes and chromosomes

The human body is made up of trillions of cells. Most of the cells contain a set of around 20,000 genes; this genetic information tells the body how to develop, grow and function. Genes are carried on structures called chromosomes, which carry the genetic information, or DNA, that makes up our genes.

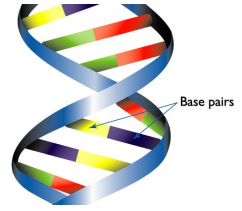
Chromosomes usually come in pairs: one chromosome from each parent. Of the 46 chromosomes, two are a pair of sex chromosomes: XX (a pair of X chromosomes) in females and XY (one X chromosome and one Y chromosome) in males. The remaining 44 chromosomes are grouped into 22 pairs and are numbered 1 to 22, approximately from the largest to the smallest. Each chromosome has a short (p) arm (from the French for small, petit) and a long (q) arm (see diagram on page 3).

In general, the right amount of genetic material is needed for correct development – not too little and not too much. How an individual develops, his/her personality, needs and achievements, is influenced by both the genetic material he or she has, and the environment in which he or she lives.

## Looking at chromosome 19p13.3

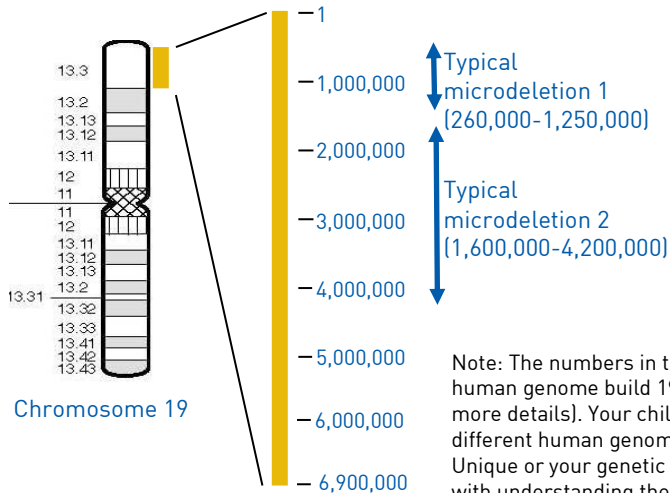
Each band of DNA contains millions of base pairs (Mb) that make up the genes. The bands of chromosome 19 are numbered outwards

from the point where the long arm meets the short arm. A microdeletion occurs when a segment of a chromosome smaller than 5Mb is missing, in this case part of the end of the short arm (p) of chromosome 19 (see diagram). The 19p13.3 region covers 0-6.9Mb on chromosome 19. The people we know about so far with a microdeletion of band 19p13.3 have between 0.2Mb to 3.6Mb of this region deleted.



1 base pair = bp  
 1,000 base pairs = 1kb  
 1,000,000 base pairs = 1Mb

Two example of typical microdeletions are shown in the diagram below: one involves the region 0.26-1.25Mb, the other 3.7-4.3Mb.



Note: The numbers in this diagram refer to the human genome build 19 (hg19; see page 4 for more details). Your child's report may refer to a different human genome build. Please contact Unique or your genetic specialist for any help with understanding the report.

## Genetic testing

Microdeletions of chromosome 19 are too small to be seen down even the highest-powered microscope. Molecular DNA technology gives a more precise understanding of the size and position of the microdeletion. This is important as scientists identify genes and pinpoint their location on chromosomes.

### Genetic testing

Techniques that are commonly used include FISH and microarrays:

- Fluorescence *in situ* hybridisation (FISH) uses fluorescent dyes to visualise under a microscope the number of copies of small sections of chromosomes. Unique publishes a separate guide to FISH

However, rare chromosome disorders may be caused by subtle changes in the chromosomes that are too small to see using a microscope.

- Microarray comparative genomic hybridisation (array CGH) is a sensitive technique which shows gains (and losses) of tiny amounts of DNA throughout the chromosomes. Array CGH identifies duplicated, disrupted or absent DNA. Unique publishes a separate guide to array CGH.

A microarray report will tell you the size of the deletion:

### arr [hg19] 19p13.3 [259395-1421222]x1 dn

**arr** The analysis was by array (arr) comparative genomic hybridisation (cgh)

**hg 19** Human Genome build 19. This is the reference DNA sequence that the base pair numbers refer to. As more information about the human genome is found, new 'builds' of the genome are made and the base pair numbers may be adjusted.

**19p13.3** The chromosome involved is 19, band 13.3 of the short p arm  
**259395-1421222**

The region from base pair 259395-1421222 has been lost. By taking the first number from the second, you get 1161827 (approximately 1.2Mb). This is the number of base pairs that are missing.

**x1** One copy of the segment of band 19p13.3, not two – one on each chromosome 19 – as you would normally expect.

**dn** *de novo* – Latin for anew, meaning that the microdeletion has arisen for the first time in that individual and is not inherited from either parent (pat means inherited from the father; mat means inherited from the mother).

## Emerging phenotype: what to expect

Chromosome changes involving chromosome 19 are uncommon and microdeletions are rarely reported. Only nine Unique members have a 19p13.3 microdeletion and 17 have been described in the medical literature (Hurgolu 1984; Archer 2005; Al-Kateb 2011; Siggberg 2011; de Smith 2011; Souza 2011; Risheg 2011; Peddibhotla 2013). The number of affected individuals is small, so it is not certain what the full range of effects of a 19p13.3 microdeletion is, but the most consistent features are:

- **Feeding and growth** – Children may have difficulties, often quite severe, with feeding and digestion.
- **Growth** – Children are often diagnosed with failure to thrive (not gaining weight): they are born small and are slow to gain weight and height as babies and young children. As older children/young adults they may be thin and slight in stature. Some have larger heads than unaffected children.
- **Sitting, moving, walking (gross motor skills):** Delays in learning to sit and walk are common. Developmental delay may be more obvious in some children than others.
- **Development: hand-eye coordination, dexterity and self-care (fine motor skills):** Children are likely to be behind their peers in some fine motor skills. Children may need extra support with toilet training.
- **Speech and language:** Communication problems are frequently reported; children often have significantly delayed speech development. Some may use

little speech and rely on signing. Speech and occupational therapy help.

- **Learning:** Learning difficulties occur in most children with a 19p13.3 microdeletion, although the level of support needed varies. Communication difficulties are likely to affect children's ability to learn.
- **Heart:** Heart problems are very common in children with a 19p13.3 microdeletion with surgery in many cases.
- **Eyesight:** Eye problems are common in children with a 19p13.3 microdeletion and children may be wearing glasses from a young age and/or require eye surgery.
- **Hearing:** Hearing problems are common in children with a 19p13.3 microdeletion and children may wear hearing aids.

## Pregnancy and birth

Many children were born small after complicated pregnancies.

Premature births (less than 37 weeks gestation) occurred in 6/18 pregnancies. Birth weights are known for 12 children and were in the range 1.4kg - 4.1kg (3lb 1oz - 9lb 1oz) with an average birth weight of 2.5kg (5lb 8oz).

A number of pregnancies were complicated by a range of problems (10/18). These include oligohydramnios (a low amount of amniotic fluid) (2/18), IUGR (intrauterine growth restriction - delayed growth of an unborn baby) (2/18), prenatal diagnosis of, for example, heart or kidney problems (3/18), maternal high blood pressure (1/18) and decreased fetal movement (2/18) (Hurgolu 1984; Archer 2005; Al-Kateb 2011; Sigberg 2011; de Smith 2011; Souza 2011; Risheg 2011; Peddibhotla 2013; Unique).

## Newborn

There may be signs of the 19p13.3 microdeletion at birth including: facial characteristics, heart defects, hypotonia (low muscle tone), low birth weight and poor feeding.

Apgar scores (measure of baby's wellbeing at birth), where commented on, were generally normal, though one girl had low scores of 3 at one minute and 5 at five minutes.

Premature birth occurred in 6/18 pregnancies. Babies may spend some time in special care, requiring extra help with feeding and/or breathing. One Unique member was born at 32 weeks gestation and spent 10 weeks in the SCBU (special care baby unit). He had heart surgery to repair a heart defect (PDA - see 'heart' section page 15) at 3 weeks old. He was a poor feeder and developed severe reflux, where stomach acid comes back up the oesophagus; gastric surgery was performed at 8 weeks old (see 'digestion' section page 6). Another child was also diagnosed with several heart defects at birth (Archer 2005). One child had vesicoureteral reflux, where there is an abnormal reverse flow of urine from the bladder to the upper urinary tract. In mild cases this does not

require treatment; in more severe cases surgery is required; he had surgery for this, hypospadias and chordee (curved penis) (Risheg 2011). Hypospadias is a condition in which the opening of the tube through which urine passes is on the underside of the penis.

Six babies needed extra breathing support in hospital after they were born (Archer 2005; Siggberg 2011; Souza 2011; Risheg 2013; Peddibhotla 2013; Unique).



## Feeding/Digestion

Many children have difficulties with feeding and digestion, sometimes requiring surgery.

Feeding and difficulties with digestion are common (14/23) (Hurgolu 1984; Al Kateb 2010; Risheg 2013; Peddibhotla 2013; Unique). Breastfeeding may be an issue with difficulty latching onto the breast combined with an inability to suck from a bottle (Unique). In one child, a swallowing study at 16 months revealed poor tongue movement and problems handling solid food were still present at 4 years old (Peddibhotla 2013). Failure to thrive (not gaining weight) is common and high calorie feeds are sometimes required (Al Kateb 2010; Unique).

Gastro-intestinal reflux (when acid from the stomach comes back up the oesophagus) is also common. Surgery may be necessary (6/23) for reflux or other gastrointestinal problems (Hurgolu 1984; Al Kateb 2010; Risheg 2013; Peddibhotla 2013; Unique). As stomach acid comes back up, a burning sensation occurs, commonly referred to as heartburn. One child had a laparoscopic Nissen fundoplication - keyhole surgery to relieve the heartburn of reflux. She also had a gastrostomy tube placement. A gastrostomy tube (also called a G-tube) is a tube inserted directly into the stomach through the abdomen that delivers food straight to the stomach, thus providing appropriate nutrition. At 23 months, she gained weight and showed significant developmental improvements (Unique).

Another child was still being tube-fed at 2½ years, although her weight was now

increasing. Feeding problems were evident in this child from 23 days old when she was diagnosed with H-type tracheoesophageal fistula. This occurs when the feeding (oesophagus) and breathing (trachea) tubes do not separate into two individual tubes, as a baby develops *in utero* (in the womb). Surgery was required, with insertion of a G-tube (Peddibhotla 2013). One Unique child also had a G-tube inserted as a newborn; this was removed at 16 months old as oral feeding improved with therapy.

Intestinal abnormalities may be apparent on ultrasounds *in utero* or immediately after birth. Two children had gastrointestinal obstructions requiring surgery (Sigggberg 2011; Risheg 2013). Another had symptoms of short bowel syndrome, a condition in which the body cannot absorb enough fluids and nutrients because part of the small intestine is missing or is not working properly; he had four intestinal surgeries (Unique). One child developed necrotising enterocolitis, where a section of the intestine becomes inflamed and the tissue eventually dies, and surgical removal was needed (Peddibhotla 2013). Constipation is reported in one Unique member.

“ He was a poor feeder (failure to thrive). Feeding has improved with therapy and at 16 months, his G-tube was removed. At that time, he would only eat pureed foods but at 2½ years he started eating table food. He still receives oral-motor therapy each week to continue to develop his eating and drinking skills but is gaining weight and doing well ” – 3 years

“ It takes her a long time to eat as she is very slow. Under the dietician, extra calories were added to her milk feeds ” – 5 years

Children may be referred to a gastroenterologist if the *STK11* gene is included in their deletion (see ‘Ongoing research’ on page 23) as a loss of this gene can cause Peutz-Jeghers syndrome (PJS) (Souza 2011; Unique). Most people with a 19p13.3 microdeletion do not have a deletion of the region where the *STK11* gene is located. The array report (see page 4) will confirm whether the *STK11* gene region is deleted and, if so, clinical examination can determine whether the features of PJS syndrome are present.

Typically, signs of this condition appear in childhood with dark blue or dark brown freckling, especially around the mouth and on the lips, fingers, or toes (see ‘skin’ on page 19). Another sign of PJS is the development of gastrointestinal tract polyps that can cause bleeding and blockages and predispose to cancer. The average age when gastrointestinal symptoms appear is 10 years; screening of the digestive tract is recommended two-yearly from the age of 25 years.

## Growth

Children are often diagnosed with failure to thrive: they are born small and are slow to gain weight and height as babies and young children. As older children/young adults they may be thin and slight in stature. Some have larger heads than unaffected children.

Children with a 19p13.3 microdeletion are often at the lower end of the normal range of weight and height for children of the same age (12/23) (Hurgolu 1984; Archer 2005; Al-Kateb 2011; Siggberg 2011; de Smith 2011; Souza 2011; Risheg 2011; Peddibhotla 2013; Unique). This may also apply into adulthood with one 23-year-old girl being short and slight (Risheg 2013). Others may be small as babies and toddlers but by four years old, for example, be of average weight for that age group (Al Kateb 2010).

Two children were heavier and taller than the average unaffected child (de Smith 2011; Risheg 2013). One of these was obese throughout early childhood and was still obese at 15 years old (de Smith 2011).

Some children have significantly larger heads than unaffected children (8/23); others have small heads (5/23) (Hurgolu 1984; Archer 2005; Al-Kateb 2011; Siggberg 2011; de Smith 2011; Souza 2011; Risheg 2011; Peddibhotla 2013; Unique).

Variations in weight, height and head size may be related to the location of the microdeletion in the 19p13.3 region and/or natural variation.

## **Development: sitting, moving, walking (gross motor skills)**

Delays in learning to sit and walk are common. Developmental delay may be more obvious in some children than others.

Some parents report a delay in learning to walk. Typically-developing babies who don't have a chromosomal disorder generally sit unaided at around 7 months and walk between 9-18 months.

There is little information in the medical literature, although global developmental delay, including gross motor skills, is reported in 14/17 people. For example, one 2-year-old boy had the gross motor skills of a one year old (Siggberg 2011). One boy sat unaided at 10 months, crawled at 10-12 months and was walking at 19 months old (Archer 2005). A girl was sitting at 11 months and walking at 15 months (Risheg 2013). At 21 months, gross motor development was delayed in one girl. She could roll and walk with support, although she could not crawl (Al-Kateb 2010). One boy started walking at 20 months (Risheg 2013) and a sixth child not until she was five years old (Souza 2011).

Hypotonia is common, particularly as newborn babies and in the early years (17/23) (Hurgolu 1984; Archer 2005; Al-Kateb 2011; Siggberg 2011; de Smith 2011; Souza 2011; Risheg 2011; Peddibhotla 2013; Unique); one teenage boy still had hypotonia at 16 years old (Archer 2005). Left-sided weakness and an unsteady gait was reported in a two year old girl (Risheg 2013).

Developmental delays are described in the majority of Unique members (8/9); in three cases these are severe, with one 5½-year-old not walking yet. Several Unique members report: sitting at 10½ months, 13 months, 14 months or 2



years old; crawling at 15 months, 2 years or 2½ years and walking at 20 months, 23 months or 3 years old. Physiotherapy is reported as highly beneficial (Unique).

“ He has just started crawling, at 2½ years. He likes to walk with support (holding both hands) and cruising around the furniture. He is attempting to pull up onto furniture but is not able to yet ”

“ He has physical therapy once a week. He has used AFOs [ankle foot orthosis - or splint - to aid walking] in the past but is currently not wearing them. He also has a gait trainer but so far has not done well walking in it, but he does like to stand in it ” – 3 years

“ She is very flexible and is delayed in milestones because of this ” – 5 years

“ She was delayed in reaching all physical milestones. At nearly 10 years old, she is still riding a bike with training wheels. She has dyspraxia [affects movement and coordination], so is often awkward and slow ”

## Development: hand-eye coordination, dexterity and self-care (fine motor skills)

Children are likely to be behind their peers in some fine motor skills. Children may need extra support with toilet training.

A delay in using their hands is commonly found in Unique members and the medical literature, although detailed information is not available (Hurgolu 1984; Archer 2005; Al-Kateb 2011; Siggberg 2011; de Smith 2011; Souza 2011; Risheg 2011; Peddibhotla 2013; Unique). Occupational therapy and physiotherapy, from a young age, help.

At nearly two years old, one child had delays in her fine motor skills. For example, she did not have a pincer grasp, where the first finger and thumb hold an object (Al Kateb 2010). One girl has fine motor skill delays at four years old. An assessment showed her to be functioning closer to the level of a 3 year old (Unique).

“ He did not reach for or play with toys until he was almost one year old. Now he can put toys in a container and take them out. He is able to feed himself with a spoon with assistance. He cannot hold or use a crayon properly or isolate his finger to push things. He has occupational therapy once a week ” – 3 years

“ She is only just starting to manage using cutlery on her own but cannot cut up food ” – 5 years

“ Her fine motor skills are reasonable. She has limited hand strength so opening doors and turning keys is difficult. Her writing is still large as she struggles to write small ” – 10 years

Children are likely to find washing and dressing difficult and be toilet-trained

later than their peers. One child was toilet-trained in the day at five years old but there was no night time control at 14 years old (Souza 2011).

“ He is in diapers and cannot brush his teeth on his own, dress or wash himself yet ” – *3 years*

“ She was out of nappies aged 4½ in the daytime and at night. She can dress and undress with a bit of help. She still needs help to brush her teeth ” – *5 years*

“ She still needs assistance with laces and buckles but can do buttons, dress herself and brush teeth. She needs assistance to do her hair and put it up. She completed a bed wetting program twice and is dry day and night now ” – *10 years*

## Speech and language

Communication problems are frequently reported; children often have significantly delayed speech development. Some may use little speech and rely on signing. Speech and occupational therapy help.

Children may start talking significantly later than their peers (12/23) (Hurgolu 1984; Archer 2005; Al-Kateb 2011; Siggberg 2011; de Smith 2011; Souza 2011; Risheg 2011; Peddibhotla 2013; Unique). Speech therapy can be started young to help with speech delay (Risheg 2013; Peddibhotla 2013). At four months, a boy had scant vocalisations and, at two years old, communication is at the one year level (Siggberg 2011). One child began to speak single words at two years old. His speech was understandable at three - four years old and at six years old, it is conversational (Risheg 2013). One boy cannot speak at three years old (Unique), one girl cannot speak at four years old (Peddibhotla 2013) and another is non-verbal at 5½ years (Unique).

Sign language or PECS (picture exchange communication system) help when speech is limited (Unique). PECS is an alternative communication method in which a child is taught to communicate with someone by giving them a card with a picture on it. Alternative communication methods, such as signing and PECs, are intended to be used in combination with speech development and not as a replacement for speech.

“ He communicates by grunting or whining. We use picture communication, where he sees two pictures of toys or food and ‘hits’ the one he wants. He does not use words or signs. We have tried signing but he prefers a choice board ” – *3 years*

“ He did not babble as a baby. He started sign language around 2 years old with about four single spoken words. Now, he has limited sentences and is confused at times. He finds it hard to remember words. Signing and PECS are useful ” – *5 years*

“ She can talk and construct full sentences but often repeats herself and

finds it difficult to find the appropriate words. The 'y' sound is difficult. We used signing initially with her, to help with, for example, when she'd like a drink” – 10 years.

## Behaviour

Children with a 19p13.3 microdeletion are frequently described as happy and engaging, although there may be some anxious and/or aggressive behaviour and social interactions may be difficult.

Anxiety or aggression may be an issue with a few children, although with the small numbers of often quite young children it is unclear how pervasive or long-lasting these may be. Some anxiety may be related to difficulties in communication. Information on behaviour comes mainly from Unique.

In the medical literature, a four year old girl had significant stranger anxiety (Peddibhotla 2013). A twelve year old girl had behavioural problems including: self-injury, aggression and temper tantrums (de Smith 2011). One teenage boy (16 years) had difficulties with social communication and social understanding (Archer 2005) and an adult (34 years old) was diagnosed with bipolar disorder (Peddibhotla 2013). Bipolar disorder, sometimes known as manic depression, is a condition that affects someone's moods, which can swing from one extreme to another, from depression to overactive and excitable or manic behaviour.

Daily behaviour can be challenging. Three Unique members report anxiety and they also describe their children chewing or mouthing objects (Unique).

“ She has very high anxiety levels, particularly when she is under pressure to communicate. Separation anxiety also occurs. She needs constant reassurance and is very anxious if her routine is changed. She can be aggressive, punching and pinching, when she is frustrated ” – 5 years

“ Socially, she has a lot of difficulty. At one stage, she had what seemed like selective mutism, because she refused to talk to anyone outside of the family. She has been through the diagnostic pathway for autism twice but it was inconclusive due to her lack of communication ” – 5 years

“ Lethargy is a problem. She can be inconsistent with behaviour, energy levels and participation in daily activities. She is sometimes anxious, and self-harms (picking scabs etc), sucks objects and is aggressive. This occurs if she is teased or doesn't understand, so tends to reacting by pushing people. She is restless when she is sleeping. She is socially delayed and immature and socialises better with other children with delays. She is very excited to see her friends. Most children the same age as her don't know her or interact with her. She likes to play alone and only occasionally plays with other children ” – 10 years

Sensory difficulties are described by one Unique member:

“ She has tactile sensitivity, to hair washing/cutting for example. Everything has to be clean ” – 5 years

Parents describe a range of activities their children enjoy (Unique):

“ He likes to sit and play with toys that light up or have cause and effect. He also enjoys playing with a ball, iPad (any kind of music app), nursery rhymes with gestures and music ” – *3 years*

“ She likes imaginative play but on her own, with her ‘babies’. Her play is often repetitive. She is creative and draws on paper ” – *5 years*

“ Favourite activities are: swimming, playing on the swing and the trampoline and pets (dog and rabbit). She mainly enjoys solitary activities ” – *10 years*

Parents often comment on their child’s special features or how happy and affectionate their child is (Unique):

“ He watches other people and children and smiles, claps his hands and laughs ” – *3 years*

“ She is very affectionate to her family ” – *5 years*

“ She is very empathetic, loving and gentle, and likes to cuddle/touch ” – *10 years*

## Learning

Learning difficulties occur in most children with a 19p13.3 microdeletion, although the level of support needed may vary. Communication difficulties are likely to affect children’s ability to learn.

Learning difficulties are apparent in most people with this microdeletion although detailed information on learning and education is not available in the medical literature (17/23) (Hurgolu 1984; Archer 2005; Al-Kateb 2011; Siggberg 2011; de Smith 2011; Souza 2011; Risheg 2011; Peddibhotla 2013; Unique). Children’s learning difficulties may become obvious at a young age and persist into later life, to a greater or lesser degree.

One Unique member started pre-school at three years, with teachers being aware of her delays. The parents opted to hold her back in pre-school with the smaller classes and more teachers rather than go into the next stage of schooling. She enjoys going to school and being with other children (Unique). Another Unique child started reading and writing at seven years old. One teenager’s learning difficulties were apparent by 13 months old. At 16 years old, he had moderate global learning difficulties with a specific problem in maths and abstract understanding. He read well, demonstrates good grammatical language structure and had an ability to understand facts but not to apply them. Dyspraxia also made learning difficult (Unique).

Delayed speech may hold children back in school (Peddibhotla 2013). A teenage girl’s learning difficulties were becoming more apparent at 14 years old (Souza 2011). One 23-year-old has significant learning difficulties and attention issues and currently lives in a group home (Risheg 2013).

Three Unique members describe severe learning difficulties:

“ She has complex learning difficulties. Her short term memory is poor and she has some difficulty concentrating, being easily distracted, particularly when under pressure; visual learning helps. She makes marks on paper (started at two years old). She is not reading. She is in mainstream school, with an SEN/IEP [Special Education Needs/Individual Education Plan] statement, with small group supervision and a focus on visual learning ” – 5 years

“ She was diagnosed with intellectual developmental delay. She is like a 5-6-year-old with her academic achievement and has a 4 year delay at this point. She struggles to concentrate and her working memory is poor, although her long-term memory is OK. She struggles with all aspects of academic learning, especially Maths and English. She is still learning to read, with early readers’ material, and requires picture prompting to help with reading etc. but we don’t use any ‘devices’. She draws simple pictures. She repeated pre-primary but is in a mainstream school with support. One-to-one learning, repetition, scaffolding and pictures all help her to learn [Scaffolding involves doing some of the work for the student who isn’t quite ready to accomplish a task independently]. She is currently being assessed for an aide (education assistant) to help in a classroom (and is likely to get 0.4-0.6 aide time). Her class consists of 12 students with a teacher and a part-time aide/education assistant ” – 10 years

## Medical concerns

As information on this microdeletion is so new, some of these features may not be associated with a 19p13.3 microdeletion. As more people are diagnosed, the picture will become clearer.

### ■ Eyesight

Eye problems are common in children with a 19p13.3 microdeletion and children may be wearing glasses from a young age and/or require eye surgery. Ten children have eye problems. The most common is strabismus (four children) – a squint, which required surgery in one case (Peddibhotla 2013; Unique). Four children are myopic - short-sighted - and wear glasses (Souza 2011; Peddibhotla 2013; Unique). Another child wears glasses to correct his longsight and a lazy eye (Peddibhotla 2013). One child had retinopathy of prematurity, which mostly occurs in premature babies and is a disease that causes abnormal blood vessel growth in the retina. No further information is available on his case: in mild cases no treatment is required, others require surgery



(Peddibhotla 2013). One child had surgery for blocked tear ducts (Risheg 2013) and right-sided ptosis (drooping eyelid) was present in another child (Peddibhotla 2013).

“ The muscles in the left eye have not developed properly. She is seeing an ophthalmologist for patching –2 hours a day – but hasn’t been tested for glasses yet as she gets very anxious and refuses to cooperate in the tests ”  
– 5 years

## ■ Hearing

Hearing problems are common in children with a 19p13.3 microdeletion. Hearing problems are present in 11/23 children (Hurgolu 1984; Archer 2005; Al-Kateb 2011; Siggberg 2011; de Smith 2011; Souza 2011; Risheg 2011; Peddibhotla 2013; Unique). Hearing loss occurred in some children after frequent ear infections (Peddibhotla 2013; Unique). Hearing problems may have been detected early on when a child failed the newborn hearing test (two children). In one of these children, no major hearing problem was found in a later follow up; in the other case, there was mild to moderate conductive hearing loss (Siggberg 2011; Peddibhotla 2013).

Conductive hearing loss occurs when sounds are unable to pass into the inner ear. This is usually due to a blockage, such as having too much ear wax, a build-up of fluid in the ear (glue ear), or an ear infection. Grommets, or very small tubes, can be surgically inserted into the ear to relieve glue ear.

Some children are reported as simply having hearing loss with no further information about the type of loss, although one wears hearing aids at 4 years old (Hurgolu 1984; Peddibhotla 2013). The other type of hearing loss is sensorineural. Two children are reported as having this. Sensorineural hearing loss occurs if the sensitive hair cells inside the cochlea are damaged, or as a result of damage to the auditory nerve (the nerve that transmits sound to brain). Two children had mixed sensorineural and conductive deafness (Archer 2005; Peddibhotla 2013). In one boy, grommets were inserted in early childhood and he wore hearing aids in both ears (Archer 2005).

One Unique child had conductive hearing loss caused by repeat ear infections and required three separate grommet insertions for glue ear at 18 months, 2 and 2½ years old. These were removed at 5½ years.

## ■ Brain

Brain imaging (MRI - magnetic resonance imaging) may be performed. This is a highly sensitive imaging technique which provides detailed information about the structure of the brain. The presence of brain anomalies may be related to the location of the microdeletion in the 19p13.3 region. In addition, it’s often not clear how any observed anomalies relate to a child’s development. However, regular screening/imaging allows any anomalies to be monitored and, if need be, treated.

Ten children had anomalies on their brain scans (Archer 2005; Al-Kateb 2011;

Siggberg 2011; Peddibhotla 2013; Unique). Two children had a haemorrhage (bleed) on the brain which led to hydrocephalus (fluid build-up) (Peddibhotla 2013). Hydrocephalus can resolve naturally (Peddibhotla 2013) but a third case required draining with a cerebral shunt (Unique).

Four children had changes in the white matter (Archer 2005; Peddibhotla 2013). White matter consists of nerve fibres which connect to each other and enabling communication between different parts of the brain. Changes in the white matter may affect brain function.

Four children had changes in the ventricles of the brain (Archer 2005; Peddibhotla 2013). These are the fluid-filled cavities which connect with the fluid in the spinal cord. The ventricles provide protection and allow the transport of molecules.

Three children had thinning of the corpus callosum (the structure that connects the right and left hand sides of the brain) (Peddibhotla 2013; Decipher). Defects in this region of the brain can be associated with features such as seizures and developmental delays in motor skills and speech development.

A Unique member had a brain cyst causing central sleep apnoea (regular pauses in breathing) and panhypopituitarism (insufficient hormone production from the pituitary gland, affecting hormones such as the growth hormone).

## ■ Heart

Heart problems are very common in children with a 19p13.3 microdeletion with surgery in many cases.

Children are likely to have a heart check. A heart anomaly, or more than one, was found in 20/25 people (Hurgolu 1984; Archer 2005; Al-Kateb 2011; Siggberg 2011; de Smith 2011; Souza 2011; Risheg 2013; Peddibhotla 2013; Decipher; Unique). In most, but not all cases, surgery was required.

Seven children had an atrial septal defect (ASD) (Al-Kateb 2011; Siggberg 2011; Souza 2011; Risheg 2013; Peddibhotla 2013; Unique). An ASD is a hole between the two upper chambers (atria) of the heart. Some ASDs are very small and may never require treatment. A large ASD may need surgery to close it.

Five children has a ventricular septal defect (VSD) (Hurgolu 1984; Archer 2005; Al-Kateb 2011; de Smith 2011; Souza 2011; Peddibhotla 2013; Unique). A VSD is a hole in the ventricular septum, which is the wall between the two ventricles – the lower pumping chambers of the heart.

VSDs are the most common congenital heart defect in the general population and, like ASDs, in most cases they're diagnosed and treated successfully with surgery, often as a young baby. For example, one baby was diagnosed with an ASD and a VSD at 5 days old and had surgery at 10 months to correct them (Souza 2011). Another child was diagnosed with some heart defects as a newborn, including a VSD – surgery was carried out at 2½ years (Archer 2005).

Two children have prominent or dilated aortic roots (the aortic root is the section of the aorta - the large artery leaving the heart - that is attached to the heart)

(Risheg 2013; Peddibhotla 2013). Two children had defects in their heart valves: details of one are not known but the other had surgical valvotomy, a procedure to enlarge narrowed heart valves, at 2½ years (Archer 2005; Risheg 2013).

Two children had surgery for Tetralogy of Fallot (four defects of the heart that occur together, including a VSD) (Peddibhotla 2013; Unique).

Two babies had persistent ductus arteriosus (PDA), a heart problem that affects some babies soon after birth (Al Kateb 2010; Siggberg 2011). The arterial duct (ductus arteriosus) is a short blood vessel connecting the two main arteries of the heart - the aorta and the pulmonary artery. Before a baby is born, the arterial duct allows blood to go around their lungs. After the baby is born and the lungs fill with air, the arterial duct is no longer needed - it usually closes by itself within the first week after birth. Sometimes the duct fails to close by itself and remains open (patent). PDA causes too much blood to be delivered to the lungs, causing a build-up of blood. This may only cause mild symptoms in young children (such as breathlessness) but if a duct is left untreated over a period of many years it may eventually lead to permanent damage to the heart and lungs. This can be life threatening as your child reaches adulthood, so surgery is generally recommended, if the PDA does not close on its own (Siggberg 2011; Unique). One Unique member had a PDA repaired as a newborn and at 2½ years, had no heart problems.

## ■ Genitals

Nine children have genital anomalies, many of which do not affect their day-to-day life.

One girl has an enlarged clitoris and another a reduction in clitoral size (Risheg 2013; Al-Kateb 2010).

Two boys have hydroceles (a collection of fluid in the scrotum) and three boys have hypospadias (Risheg 2013; Peddibhotla 2013; Unique). This is a condition in which the opening of the urethra, through which urine passes, is on the underside of the penis. Hypospadias does not always require surgery (Unique); in other cases, it is corrected by surgery, as was the associated chordee (curved penis) (Risheg 2013).

## ■ Kidneys

Eight people have kidney anomalies (Siggberg 2011; Risheg 2013; Peddibhotla 2013; Decipher).

Four people are missing a kidney (Archer 2005; Siggberg 2011; Peddibhotla 2013). It is possible to be healthy with only one kidney, providing the other is fully functioning; the remaining kidney may become enlarged, to compensate for the missing one (Siggberg 2011).

Hydronephrosis occurred in four people (Peddibhotla 2013; Risheg 2013; Decipher). This is a condition where one or both kidneys become stretched and swollen as a result of a build-up of urine inside the kidney(s). In one case, this was severe (Siggberg 2011). Most cases of hydronephrosis are treated surgically (Siggberg 2011).



Three children had vesicoureteral reflux (VUR), where there is an abnormal reverse flow of urine from the bladder to the upper urinary tract (Decipher; Unique). A low dose of antibiotics, often until a child is 2-3 years old, will prevent urinary tract infections and any associated damage to the kidneys. Children who do not grow out of VUR might need surgery.

One child had a ureterocele, a swelling at the bottom of one of the tubes (ureters) that carry urine from the kidney to the bladder (Archer 2005). Regular observations are necessary to monitor kidney function and minimise the risk of infection; large ureteroceles may require surgery.

## ■ Spine/Bones

Five children have scoliosis (curved spine). This is relatively common in the general population and mild cases do not require any treatment (Risheg 2013; Peddibhotla 2013; Unique). In two of these people, the upper region of the spine has a pronounced outward curve (kyphosis) (Souza 2011; Unique). This may not cause any symptoms other than the back appearing hunched. In some cases there is back pain and stiffness. A back brace may be needed but surgery is rarely required.

One Unique member had an MRI scan of the lower spine due to a dimple at the base of the spine. In this case, no abnormalities were detected.

One person has delayed bone age (Risheg 2013); a skeletal survey ruled out a connective tissue disorder (Stickler syndrome) and epiphyseal dysplasia (a rare genetic disorder which affects the growing ends of bones). A Unique member has had two fractured forearms at around six years old. A bone scan showed low bone density. Another six year old had a dislocated hip with a pelvic deformity (Unique). A girl has an extra rib (Al Kateb 2010).

Four children have anomalies of their limbs. A two year old had unexplained bowing of her legs (Risheg 2013). One child had hemihyperplasia, a congenital disorder where one side of the body grows more than the other. In this case, it developed in the right leg around three years old (Peddibhotla 2013). A 14 year old girl has cubitus valgus, where the forearm is angled away from the body to a greater degree than normal when fully extended (Souza 2011). A boy has limited arthrogryposis meaning he has joint contractures - some of his joints don't move as much as normal (Unique).

Four children have joint laxity (Archer 2005; Peddibhotla 2013; Unique), which is marked in one case in the knees and feet (Archer 2005).

At four years old, a girl was diagnosed with arthritis in her knees, requiring medication and attention from a paediatric arthritis specialist (Unique).

## ■ Feet and hands

Children with a 19p13.3 microdeletion may have hands or feet that look different to normal (10/23). Some of these changes, particularly to the feet, may impede movement and flexibility.

Two children have a club foot, one on the right and one on the left. These were

treated by manipulation and casting (Peddibhotla 2013). Another child has mild right rocker bottom feet, where the foot resembles the bottom of a rocking chair (Peddibhotla 2013).

One child has pes cavus. This is a high arch of the foot that does not flatten with weight bearing; it can be corrected with physiotherapy or, in more severe cases, surgery (Peddibhotla 2013).

Two children have short toes, in one case just the little toes (de Smith 2011; Archer 2005). One child had large second toes, longer than her big toes, and both little toes curled inwards (Unique). Another child had small feet at 21 months, with a puffy top of the foot (Al-Kateb 2010).

Two children have a wide gap between the first and second toes (Souze 2011; Unique).

Two children have small hands with short fingers (de Smith 2011; Risheg 2013).

Two children have thin spoon-like nails (Risheg 2013). One child has overlapping fingers and another has ulnar deviation of both hands (causing the fingers to bend towards the little finger) (Peddibhotla 2013). Two children have long fingers (Archer 2005; Al-Kateb 2010), with a single crease on the palm of the right hand (Al-Kateb 2010).

### ■ Facial features

Children with a 19p13.3 microdeletion may not look markedly different from other children or other family members. Some have slightly unusual features which include: a broad forehead, deep-set eyes, a long and/or smooth philtrum (the vertical groove between the base of the nose and the border of the upper lip) and bushy eyebrows (Hurgolu 1984; Archer 2005; Al-Kateb 2011; Siggberg 2011; de Smith 2011; Souza 2011; Risheg 2013; Peddibhotla 2013; Unique).

A number of children have external ear anomalies (also see 'hearing') (11/23).

The ears are often low set (5/23) and/or have tags or are uneven in size or shape (10/23) (Al-Kateb 2011; Risheg 2013; Peddibhotla 2013; Unique).

A high narrow palate (roof of the mouth) is found in 5/23 children (Al-Kateb 2011; Risheg 2013; Peddibhotla 2013; Unique). Four children had a cleft palate (Archer 2005; Peddibhotla 2013; Unique); one of these children also had a tongue anomaly and a bifid uvula, meaning that the tissue that dangles at the back of the throat between the tonsils has two parts instead of one (Unique). Cleft palates can be repaired surgically as is reported in one boy, at 10 months of age (Archer 2005). Two other children also had an abnormally-shaped uvula (Risheg 2013). A two year old had a hypotonic tongue (making speech difficult) and large tonsils, which contributed to sleep apnoea (a pause in breathing) (Siggberg 2010). A girl had difficulty keeping her tongue in her mouth as a baby (Unique).

One 23 year old was described as having disorganised teeth (Risheg 2013); another adult had prominent incisors with an overbite and a misplaced right canine on the lower jaw at 34 years old (Peddibhotla 2013). Two Unique members also had atypical teeth; in one case, this was a tooth enamel anomaly

(Unique).

Some children have significantly larger heads than unaffected children (8/23); others have small heads (5/23) (Hurgolu 1984; Archer 2005; Al-Kateb 2011; Siggberg 2011; de Smith 2011; Souza 2011; Risheg 2013; Peddibhotla 2013; Unique). One three year old with a large head has fluid around his brain that did not resolve on its own and a subdural peritoneal shunt was used (Unique). This involves inserting a catheter (a thin, flexible tube) into the fluid-filled space in the brain and diverting the excess fluid to the abdomen.

Two children have torticollis (a twisted neck, turning the head to one side) (Risheg 2013; Peddibhotla 2013).

## ■ Skin

Skin conditions, of various types, are described in 8/23 people.

At birth, one girl had a large nasal dermoid cyst (saclike growths that are present at birth and usually sit over the bridge of the nose) (Peddibhotla 2013); a boy also had a cyst on his nose (Unique).

One Unique member was born with a strawberry haemangioma (birthmark consisting of a benign – noncancerous – tumour of blood vessels) which disappeared without treatment by the time he was one year old. Two children in the medical literature also had haemangiomas (Risheg 2013; Peddibhotla 2013). One boy had several: on the left hand, neck and head. By four years old, the hand one had disappeared (Peddibhotla 2013).

Two children had cutis aplasia (missing skin) on the head which were evident at birth (Al-Kateb 2010; Siggberg 2011). Small areas of missing skin heal over time without treatment; other larger areas may require a skin graft.

A 14-year-old boy had black pigment spots on the eyelids, nose, cheeks and lips and has been diagnosed with Peutz-Jeghers Syndrome (see 'digestion' page 6 and 'ongoing research' page 23) (Souza 2011). A girl also had similar spots on her lips (Unique).

One child had a tendency to severe, recurrent keloid formation (overgrowth of scar tissue when a wound is healing), which were particularly prominent post-surgical procedures. These were reduced in size by immunoglobulin (antibody) therapy (Archer 2005).

One Unique child had extra hair at the top of her back and an extra crease in her lower back.

## ■ Seizures

Seizures occur in a small number of people

No Unique members report seizures. Three individuals in the medical literature had seizures. One three year old had recently developed seizures (Peddibhotla 2013). A teenager had had one seizure at 5 years old and there had been no recurrence (Souza 2011). Another teenager, now aged 16, had developed seizures when he was 8 years old. These were now well controlled on medication (Archer 2005).

## General wellbeing

General wellbeing was good in most Unique members, although they may be more prone to infections, particularly ear infections (Unique) (see 'hearing' page 14).

A boy had a utricle (cyst) in his bladder and frequent urinary tract infections. He also had low blood cell counts of white blood cells (immune system cells which fight infections) and platelets (involved in blood clotting) (Unique). Another had a problem with proconvertin factor VII (a molecule that is involved in blood clotting) (Unique). A third child also had low white blood cell counts and problems with blood clotting (Risheg 2013).

One child had numerous predominantly upper respiratory tract infections with low antibody levels, and abnormally developed white blood cells. As a young child he had a food allergy to several pulses (lentils, baked beans and chick peas) but tolerated these at 16 years old. Injections of antibodies were administered for the recurrent infections (Archer 2005).

Breathing problems are occasionally described, more commonly in newborn babies who needed help with breathing. One boy has an abnormal left lung and has frequent lung infections (Unique). Tracheomalacia was found in one child (Unique). This occurs when the trachea (windpipe) leading from the mouth to the lungs is floppy. A child may grow out of this condition or use an oxygen mask to help with breathing. Some cases require surgery. Two children were hospitalised for pneumonia (Peddibhotla 2013); one required repeat hospitalisations.

Sleep is not generally a problem, although two Unique members do mention restless and fitful sleep.

*“ It takes her a long time to go to sleep. She is very restless in bed but will not sleep if she cannot feel me next to her and she checks [that] constantly at night. She has nightmares from her anxiety. It helps if there is lots of reassurance and a relaxed atmosphere going to bed. She is now prescribed melatonin to help her fall asleep earlier ” – 5 years*

Four children have sleep apnoea (a pause in breathing) (Souza 2011; Siggberg 2011; Risheg 2013; Peddibhotla 2013). At five months, a girl was diagnosed with a floppy epiglottis (the flap that prevents food and liquid going down the trachea or windpipe), with obstructive sleep apnoea requiring a tracheostomy (an incision in the windpipe to help with breathing) (Risheg 2013).

*“ He had minor respiratory problems as a newborn and required continuous positive nasal airway pressure for one day. At 1½ months, he started to have apnoeic spells (a pause in breathing) and somnography confirmed a diagnosis of central sleep apnoea. After treatment [with medication], his condition improved. However, the main problem is apnoeic spells which have become obstructive ” – 2 years*

One child has a spleen and liver anomaly, although no more information is available (Unique). Another had prolonged jaundice as a baby (Unique). One child has hyperhydrosis (excessive sweating) (Unique). Another had an underactive thyroid (hypothyroidism) (Peddibhotla 2013). Two children have seasonal allergies (Unique) and one child has asthma (Peddibhotla 2013; Unique). Three girls have widely-spaced nipples (Al-Kateb 2010; Risheg 2013; Peddibhotla 2013).

## What were the first signs?

Many children do have some indications of a chromosome anomaly when they are born (11/23). Features that are commonly detected are: premature birth and/or low birth weight, facial (for example, a broad forehead or deep-set eyes), heart defects, gastric anomalies, respiratory problems and hypotonia.

Parents usually report that there was something different in the first year, although a diagnosis may not be made until they are older. The age at diagnosis of four Unique members was: 14 months, 3 years, 6 years and 16 years old. In the medical literature, six children were diagnosed as newborn babies (Hurgolu 1984; Risheg 2013; Peddibhotla 2013), one at 15 months old, one at 10 years old and one at aged 34 years (Peddibhotla 2013). In the early months and years, many children are diagnosed with failure to thrive and developmental delays – speech and motor skills - are found in the majority of children (Hurgolu 1984; Archer 2005; Al-Kateb 2011; Siggberg 2011; de Smith 2011; Souza 2011; Risheg 2013; Peddibhotla 2013; Unique).

*“ She presented with a complex developmental disorder with delay and was referred to a geneticist at 4 years old ” – 10 years*

## Therapy/routine medical appointments

Regular therapy appointments are highly beneficial with ongoing work to develop skills in all environments

A programme of regular therapy can be very helpful in coping with the different features of a 19p13.3 microdeletion. Some of these are mentioned in the relevant section above but outlined below are some examples of the most common with their aims and benefits. Parents often comment on the importance of collaboration between therapists, parents and other adults caring for their children and therefore the continuing development of skills in all settings – home and school.

**Speech and language therapy (SALT):** Speech and language therapists work with any child with a communication problem. Eating involves similar mouth and tongue control to speaking and so speech therapy also helps if there are feeding issues. Speech therapy can be started as young as three months and is commonly used by Unique members.

*“ She attends a language development centre. She has had speech therapy from 23 months, which is ongoing and is also improving her ability to read ” – 10 years*

**Occupational therapy (OT):** Occupational therapists work with children to increase their ability to cope with the tasks presented by everyday life. Their work not only covers areas like dressing but also less obvious ones like writing skills and difficulties with perception. Occupational therapy improves fine motor skills, self-care skills and can also help deal with sensory processing disorder and attention span issues. It can be beneficial into the teenage years.

“ He has occupational therapy once a week to help with fine motor skills ”  
– 3 year

“ She has occupational therapy from 3-8 years old to improve gross and fine motor skills ” – 10 years

**Physiotherapy:** Physiotherapists use exercises to help people gain and keep the best possible use of their bodies. Unique members have reported that physiotherapy has improved gross motor skills and, for example, balance.

“ She has physiotherapy to improve her postural control. Due to low muscle tone, there is only some improvement ”– 10 years

Oral motor therapy may help with feeding problems (Unique).

Routine medical appointments that form part of the life of a family member with a 19p13.3 microdeletion might include some of the following medical specialists:

- **a cardiologist** – a specialist in the structure and function and disorders of the heart
- **an endocrinologist** – a specialist in treating conditions that are caused by hormone imbalances in the body
- **a gastroenterologist** – a specialist who treats diseases of the digestive system
- **a nephrologist** – a specialist who treats kidney diseases
- **a neurologist** – a specialist in treating conditions that affect the nervous system, which is made up of the brain, nerves and spinal cord
- **an ophthalmologist** – a specialist in treating eye problems
- **a paediatrician** – a specialist in treating children
- **a urologist** – a specialist in treating conditions that affect the urinary system

Other routine appointments might include:

- **a continence adviser** – a nurse specialising in bladder and bowel problems
- **an educational psychologist** – to help children and teenagers having trouble progressing with their education, for example, due to a learning disability
- **a geneticist** – a doctor who specialises in genetics
- **a genetic counsellor** – a health professional with specialized training and experience in the areas of medical genetics and counselling

- **a health visitor** – a qualified nurse with extra training who helps families with babies and young children
- **a social worker** – to give advice about practical issues such as benefits, housing and day care

## Helping other parents

Parents of people with a 19p13.3 have provided comments, concerns and advice that helped them, particularly when their child was first diagnosed:

“ When she was first diagnosed, we wanted to know the prognosis and her future learning capacity. These questions remain unanswered but we have found it was best to always treat her symptoms and weaknesses; it’s important to be under a good developmental paediatrician to oversee treatment needs ”

“ When he was first diagnosed, we wanted to know what to expect in the future (development). Our developmental paediatrician and other special needs parents gave the most helpful answers ”

“ My main question still is how this will affect her as she gets older. When she was first diagnosed, I wish I had known about her eyesight difficulties ”

“ Don’t give up. Do what you think is right. Don’t be afraid to pursue other avenues if you are not happy ”

## What is the outlook?

We can’t be sure yet but there appears to be no reason why people who are healthy should not enjoy a normal lifespan. Children who have learning and developmental disabilities often do not have major health problems. In those individuals with heart problems, close monitoring and surgery may be required.

## Puberty and Fertility

Six people with a 19p13.3 microdeletion are known to be older than 14 years old (Archer 2005; de Smith 2011; Risheg 2013; Peddibhotla 2013; Unique). There are no details available other than a report that the onset of normal menstrual cycles was at 13 years old in one girl (de Smith 2011). There are no known cases of children born to someone with a 19p13.3 microdeletion.

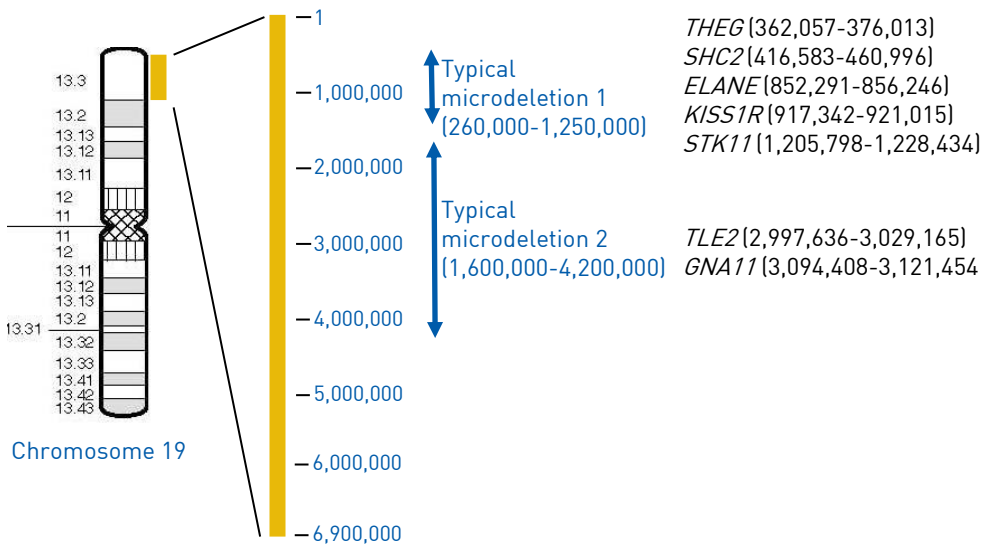
## Ongoing research: candidate genes

The 19p13.3 region is located at 0-6.9Mb on chromosome 19 (hg 19). The variation in size of the microdeletions (0.2Mb to 3.6Mb) within this region can mean anything from 5 genes to over 100 genes can be missing (Al-Kateb 2010; Souza 2011; Peddibhotla 2013). Candidate genes that might play a part in the features associated with a 19p13.3 microdeletion include:

- *THEG* plays a role in the assembly of proteins, the development of the hormone and reproductive systems, and may lead to decreased body size.

- *SHC2* is involved in the maturation of sensory neurons (nerve cells) in the brain and may be involved in vision problems/hearing loss
- *ELANE* has been associated with effects on the immune system and the ability to fight infections
- *STK11* deficiency causes Peutz-Jeghers syndrome - pigmented skin spots and digestive problems.
- *KISS1R* regulates a number of functions including hormone regulation, onset of puberty, brain and behaviour. Feeding issues, kidney problems and learning difficulties have all been related to this gene.
- *ACTA1* is involved in brain function and has been associated with hypotonia and motor skills developmental delay.
- *GNA11* and *TLE2* are linked to facial and cardiac anomalies.

Some genes (and their base pair position) located on 19p13.3:



Note: The numbers in this diagram refer to the human genome build 19 (hg19; see page 4 for more details). Your child's report may refer to a different human genome build. Please contact Unique or your genetic specialist for any help with understanding the report.



As these are gene-dense regions, there are likely to be a number of different genes involved; the precise size and location of the deletion will govern which genes are deleted. It is also important to remember that, whilst identifying the gene(s) responsible for certain features of 19p13.3 microdeletions is valuable and may help guide future research, it does not lead directly to immediate improved treatment. In addition, even if a gene is missing, it does not always mean that the associated feature(s) will be evident or that there is a direct relationship between an absent gene and a particular feature. Other genetic and environmental factors often have a role in determining the presence or absence of a particular feature.

## Why did this happen?

A blood test to check both parents' chromosomes allows parents to find out how the 19p13.3 microdeletion occurred. The child may have inherited the microdeletion from a mother or a father. Six cases are known to be inherited (Peddibhotla 2013; Decipher). However, in the cases where both parents have been tested and both parents have normal chromosomes, the microdeletion occurred in the child for the first time and was not inherited. Geneticists call this '*de novo*' which means 'new'. *De novo* 19p13.3 microdeletions are caused by a change that occurred when the parents' sperm or egg cells formed, or possibly during formation and copying of the early embryonic cells, when the egg and sperm joined.

There is nothing you, as a parent, did to cause the microdeletion, either before or during the pregnancy. Parents should feel reassured that no lifestyle change – environmental or dietary – would have prevented it from occurring.

## Can it happen again?

Where both parents have normal chromosomes, it is unlikely that another child will be born with a 19p13.3 microdeletion or any other chromosome disorder. Very rarely (less than 1%), both parents have normal chromosomes by a blood test, but a few of their egg or sperm cells carry the 19p13.3 microdeletion. This is called [germline mosaicism](#) and it means that parents whose chromosomes appear normal when their blood is tested can have more than one child with the deletion.

In families where the 19p13.3 microdeletion has been inherited from a parent, the possibility of having another child – either a girl or a boy – with the 19p13.3 microdeletion rises to 50% in each pregnancy. However, the effect of the microdeletion on the child's development, health and behaviour cannot be reliably predicted.

Your genetics centre should be able to offer counselling before you have another pregnancy.

## References

**Al-Kateb H**, Hahn A, Gastier-Foster JM, Jeng L, McCandless SE, Curtis CA. 2010. Molecular characterization of a novel, de novo, cryptic interstitial deletion on 19p13.3 in a child with a cutis aplasia and multiple congenital anomalies. *American Journal of Medical Genetics*: 3148-3153.

**Archer HL**, Gupta S, Enoch S, Thompson P, Rowbottom A, Chua I, Warren S, Johnson D, Ledbetter DH, Lese-Martin C, Williams P, Pilz DT. 2005. Distinct phenotype associated with a cryptic subtelomeric deletion of 19p13.3-pter. *American Journal of Medical Genetics*: 38-44.

**de Smith AJ**, van Haelst MM, Ellis RJ, Holder SE, Payne SJ, Hashim SK, Froguel P, Blakemore AI. 2011. Chromosome 19p13.3 deletion in a patient with macrocephaly, obesity, mental retardation, and behavior problems. *American Journal of Medical Genetics*: 1192-1195.

**Hurgoiu V**, Suciuc S. Occurrence of 19p- in an infant with multiple dysmorphic features. 1984. *Annals of Genetics*: 56-57.

**Peddibhotla S**, Khalifa M, Probst FJ, Stein J, Harris LL, Kearney DL, Vance GH, Bull MJ, Grange DK, Scharer GH, Kang SH, Stankiewicz P, Bacino CA, Cheung SW, Patel A. 2013. Expanding the genotype-phenotype correlation in subtelomeric 19p13.3 microdeletions using high resolution clinical chromosomal microarray analysis. *American Journal of Medical Genetics*: 2953-2963.

**Risheg H**, Pasion R, Sacharow S, Proud V, Immken L, Schwartz S, Tepperberg JH, Papenhausen P, Tan TY, Andrieux J, Plessis G, Amor DJ, Keitges EA. 2013. Clinical comparison of overlapping deletions of 19p13.3. *American Journal of Medical Genetics*: 1110-1116.

**Siggberg L**, Olsén P, Nântö-Salonen K, Knuutila S. 2011. 19p13.3 aberrations are associated with dysmorphic features and deviant psychomotor development. *Cytogenetics and Genome Research*: 8-15.

**Souza J**, Fauz F, Sotomaior V, Filho AB, Rosenfeld J, Raskin S. 2011. Chromosome 19p13.3 deletion in a child with Peutz-Jeghers syndrome, congenital heart defect, high myopia, learning difficulties and dysmorphic features: Clinical and molecular characterization of a new contiguous gene syndrome. *Genetics and Molecular Biology*: 557-561.



**Notes:**

# Inform Network Support



Understanding Chromosome & Gene Disorders

## Rare Chromosome Disorder Support Group,

The Stables, Station Road West, Oxted, Surrey. RH8 9EE. UK

Tel: +44(0)1883 723356

[info@rarechromo.org](mailto:info@rarechromo.org) | [www.rarechromo.org](http://www.rarechromo.org)

## Join Unique for family links, information and support.

Unique is a charity without government funding, existing entirely on donations and grants. If you can please make a donation via our website at:

[www.rarechromo.org/donate](http://www.rarechromo.org/donate)

Please help us to help you!

This leaflet is not a substitute for personal medical advice. Families should consult a medically qualified clinician in all matters relating to genetic diagnosis, management and health. The information is believed to be the best available at the time of publication. It was compiled by Unique and reviewed by Dr Bronwyn Kerr, Consultant Clinical Geneticist, Central Manchester University Hospital NHS Foundation Trust, UK.

Version 1.0 [CW]

Copyright © Unique 2016