

Support and Information



Rare Chromosome Disorder Support Group,
G1, The Stables, Station Road West, Oxted, Surrey RH8 9EE, United Kingdom
Tel/Fax: +44(0)1883 723356
info@rarechromo.org | www.rarechromo.org

Join Unique for family links, information and support.

Unique is a charity without government funding, existing entirely on donations and grants. If you can, please make a donation via our website at www.rarechromo.org Please help us to help you!


There is a Facebook group for families affected by duplication/ trisomy of chromosome 16p13.3 at www.facebook.com/groups/149100905185837

Unique lists external message boards and websites in order to be helpful to families looking for information and support. This does not imply that we endorse their content or have any responsibility for it.

This information guide is not a substitute for personal medical advice. Families should consult a medically qualified clinician in all matters relating to genetic diagnosis, management and health. Information on genetic changes is a very fast-moving field and while the information in this guide is believed to be the best available at the time of publication, some facts may later change. Unique does its best to keep abreast of changing information and to review its published guides as needed. The guide was compiled by Unique and reviewed by Professor Koen Devriendt, director, Human and Developmental Genetics Programme, KU Leuven and Dr Bernard Thienpont, laboratory of Translational Genetics, KU Leuven, Belgium. 2013 (PM)

Copyright © Unique 2013

Rare Chromosome Disorder Support Group Charity Number 1110661
Registered in England and Wales Company Number 5460413



16p13.3 duplications and microduplications



Sources

The information in this guide is drawn partly from 26 cases in the published medical literature and other relevant papers:

Thienpont 2007; Marangi 2008; Dallapiccola 2009; Thienpont 2010; Chen 2012; Mattina 2012; Tüysüz 2012; Demeer 2013; Li 2013.

For the discussion of larger duplications, the following sources have been consulted:

Hebebrand 1994; Kokalj-Vokac 2000; Martin 2002; Tschernigg 2002; de Ravel 2005; Sommer 2006; Digilio 2009.

The first-named author and publication date are given to allow you to look for the abstracts or original articles on the internet in PubMed

(www.ncbi.nlm.nih.gov/pubmed/). If you wish, you can obtain most articles from Unique.

In addition, this guide draws on a survey of members of Unique conducted in 2013, referenced Unique. When this guide was compiled, Unique had nine members with a pure duplication of 16p13.3. They ranged in age from a teenager of 13 years to a young baby.

16p13.3 duplications and microduplications

A 16p13.3 duplication is a genetic condition that occurs when there is a small piece of extra genetic material (DNA) on one of the 46 chromosomes – chromosome 16. The genetic change usually affects development, and sometimes health and behaviour as well. But how much it affects individuals, and the ways in which it affects them, can vary a lot.

Genes and chromosomes

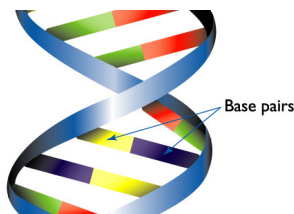
Our bodies are made up of trillions of cells. Most of the cells contain a set of around 20,000 different genes; genetic information tells the body how to develop, grow and function. Genes are carried on structures called chromosomes. Chromosomes usually come in pairs, one chromosome from each parent. Of the 46 chromosomes, two are a pair of sex chromosomes: (two Xs for a girl and an X and a Y for a boy). The remaining 44 chromosomes are grouped into 22 pairs and are numbered 1 to 22, approximately from largest to smallest. These are called autosomes. Each chromosome has a short (p) arm (from petit, the French for small) and a long (q) arm.

In general, the right amount of genetic material is needed for correct development – not too little and not too much. How an individual develops, his/her personality, needs and achievements, are influenced by both the genetic material he or she has and the environment in which he or she lives.

Looking at chromosome 16p13.3

Chromosomes can't be seen with the naked eye, but if they are stained and magnified under a microscope, each one has a distinctive pattern of light and dark bands. Each band contains millions of base pairs of DNA. Base pairs are the chemicals in DNA that form the ends of the 'rungs' of its ladder-like structure. Chromosome 16 has over 90 million base pairs. Band 16p13.3 has about 7,900,000 base pairs. This sounds a lot, but is actually a tiny fraction of the total; the whole of band 16p13.3 is about a quarter of one per cent of the total DNA in each cell.

In the diagram of chromosome 16 on page 3, you can see the chromosome bands are numbered outwards from the point where the long arm meets the short arm. You will find 16p13.3 at the very top, a light band. Beneath it is band 16p13.2, a dark band. The part of band 16p13.3 that this guide focuses on is marked with a red bar. It is near the middle of the 16p13.3 band.



1 base pair = bp
1,000 base pairs = 1kb
1,000,000 base pairs = 1Mb

Hebebrand et al. American Journal of Medical Genetics A. 1994 Sep 15; 54(3): 268-70. PMID: 7810587

Kokalj-Vokac 2000: A case of insertional translocation resulting in partial trisomy 16p

Kokalj-Vokac et al. Annales de Genetique 2000 Vol 43 131-135. PMID: 11164194

Li 2013: Phenotypic expansion of the interstitial 16p13.3 duplication: A case report and review of the literature.

Li et al. Gene. 2013 Dec 1;531 (2):502-5. PMID: 24035902

Marangi 2008: Duplication of the Rubinstein-Taybi region on 16p13.3 is associated with a distinctive phenotype.

Marangi et al. American Journal of Medical Genetics A. 2008 Sep 15;146A (18):2313-7. PMID: 18688873

Martin 2002: "Molecular rulers" for calibrating phenotypic effects of telomere imbalance.

Martin et al. Journal of Medical Genetics 2002 Oct; 39 (10): 734-40. PMID: 12362030

Mattina 2012: Interstitial 16p13.3 microduplication: case report and critical review of genotype-phenotype correlation.

Mattina et al. European Journal of Medical Genetics 2012 Dec; 55(12):747-52. PMID: 23032921

Sommer 2006: Trisomy 16p: a longitudinal profile and photo essay.

Sommer et al. American Journal of Medical Genetics A. Jan 15;140 (2):174-9. PMID: 16353251

Thienpont 2007: A microduplication of CBP in a patient with mental retardation and a congenital heart defect.

Thienpont et al. American Journal of Medical Genetics A. 2007 Sep 15;143A (18):2160-4. PMID: 17702016

Thienpont 2010: Duplications of the critical Rubinstein-Taybi deletion region on chromosome 16p13.3 cause a novel recognisable syndrome.

Thienpont et al. Journal of Medical Genetics 2010 Mar;47 (3):155-61. PMID: 19833603

Tschernigg 2002: Terminal tandem duplication of 16p: a case with "pure" partial trisomy (16)(pter-->p13).

Tschernigg et al. Genetic Counselling 2002;13 (3): 303-7. PMID: 12416638

Tüysüz 2012: A microduplication of the Rubinstein-Taybi region on 16p13.3 in a girl with a bilateral complete cleft lip and palate and severe mental retardation.

Tüysüz et al. Clinical Dysmorphology 2012 Oct; 21(4):204-7 PMID: 22664659

monitored for pulmonary hypertension and the observation that children may be susceptible to pulmonary vascular disease (a condition that affects the blood supply in the lungs) (Digilio 2009).

Development

Nearly everyone reported in the medical literature with a duplication of 16p13.3 experiences some level of developmental delay and needs some support with their learning, but the difficulties faced by those with larger duplications are more obvious earlier and are more severe. Both groups experience specific speech delay and difficulties, but those with a larger duplication are much more likely not to speak than those with 16p13.3 duplication syndrome, and to use other ways to communicate such as signing. Where learning difficulties have been characterised, they have ranged between moderate and profound.

Facial features

Both groups have typical facial features. There is some overlap, but the 'typical faces' are different. In addition to features seen in 16p13.3 duplication syndrome, some children with a larger duplication have blonde, fine hair and sparse eyebrows, large cupped ears, an outward curling upper lip, widely spaced teeth, and a round face which lengthens with age. The small lower jaw and chin (micrognathia) can develop into a large jaw that juts forward.

(Hebebrand 1994; Kokalj-Vokac 2000; Martin 2002; Tschernigg 2002; de Ravel 2005; Sommer 2006; Digilio 2009)

References

Chen 2012: Clinical and molecular delineation of 16p13.3 duplication in a patient with congenital heart defect and multiple congenital anomalies.

Chen et al. American Journal of Medical Genetics A. 2012 Mar;158A (3):685-8. PMID: 22307725

Dallapiccola 2009: Expanding the phenotype of duplication of the Rubinstein-Taybi region on 16p13.3.

Dallapiccola et al. American Journal of Medical Genetics A. 2009 Dec;149A (12):2867-70. PMID: 19921635

Demeer 2013: Duplication 16p13.3 and the CREBBP gene: confirmation of the phenotype.

Demeer et al. European Journal of Medical Genetics 2013 Jan; 56(1):26-31. PMID:23063576

de Ravel 2005: Trisomy of chromosome 16p13.3 due to an unbalanced insertional translocation into chromosome 22p13.

de Ravel et al. European Journal of Medical Genetics 2005 Jul-Sep; 48(3): 355-9. PMID: 16179232

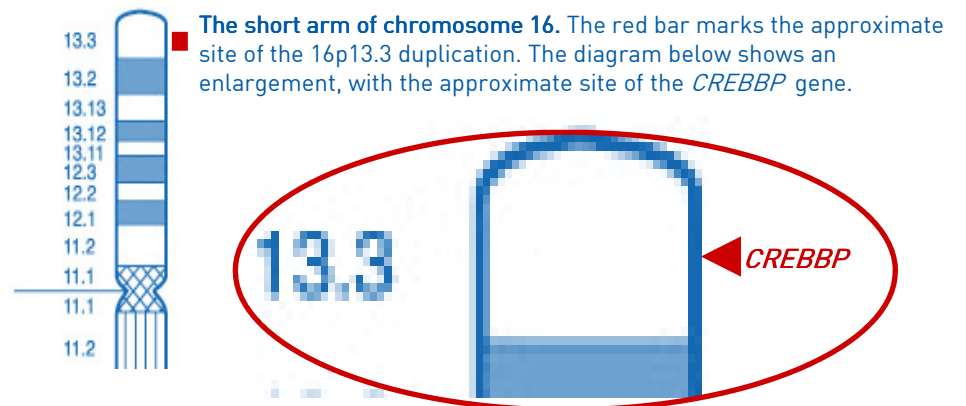
Digilio 2009: 16p subtelomeric duplication: a clinically recognizable syndrome.

Digilio et al. European Journal of Human Genetics 2009 Sep;17(9):1135-40. PMID: 19293839

Hebebrand 1994: Partial trisomy 16p in an adolescent with autistic disorder and Tourette's syndrome.

16p13.3 duplication syndrome

When a particular set of developmental features occurs in a recognisable and consistent pattern in enough people, as a result of a single cause, the condition is called a syndrome. The essential features of a 16p13.3 duplication do occur in this way, so the disorder is known as **16p13.3 duplication syndrome**. The essential features of the syndrome seem to occur when a gene known as *CREBBP* is duplicated (see [Genes](#) page 23). The 16p13.3 duplication syndrome is called an 'emerging syndrome' because it has only recently been identified – in 2010; only 26 affected individuals have been reported in the medical literature; and most of them have duplications much larger than the *CREBBP* gene thought to be the cause of the syndrome. However, when you compare the features of a core group of five people with tiny duplications including the *CREBBP* gene and in one case very little more, they are very similar to the features of people with a much larger duplication. The smallest reported duplication known to cause 16p13.3 duplication syndrome is 240kb. As more people with the syndrome are identified, what we know about its effects will be refined (Thienpont 2010; Mattina 2012; Demeer 2013; Li 2013).



The 16p13.3 duplication syndrome is estimated to occur in about 1 in every 97,000 to 146,000 newborn babies (Thienpont 2010; Cooper 2011). When the *CREBBP* gene is missing or changed so that it does not function properly, a syndrome known as Rubinstein-Taybi syndrome (RTS, 16p13.3 deletion syndrome) occurs. Even though the same gene is implicated, it is not helpful to compare the features seen in people with RTS and those with the 16p13.3 duplication syndrome.

Has everyone with a 16p13.3 duplication got the same amount of extra DNA?

No: everyone is different. So far as we know, there are no especially fragile places in the 16p13.3 region where the chromosome is likely to break. Some people have got a lot of extra DNA and extra genes, others only extra copies of the *CREBBP* gene and one or two other genes. The *CREBBP* gene itself measures 156kb, while the entire 16p13.3 band in which it is found measures 7.9Mb, or 50 times as much. The whole 16p13 band of which 16p13.3 is a part measures 16.8Mb, or 108 times as much as the *CREBBP* gene. There is a small group of five individuals reported in the medical literature with tiny duplications consisting mostly of the *CREBBP* gene. The differences between this group and the larger group of 21 other people reported are shown in the table [Main features and Other features](#) (page 24).

The differences between people who all have a 16p13.3 duplication are probably largely explained by the other duplicated genes they have. People with the typical features of the syndrome and a small duplication of *CREBBP* and only a few other genes are said to have [16p13.3 duplication syndrome](#). People with a larger duplication with more extra DNA and genes have a [16p13.3 duplication](#) (see pages 25-26).

Larger duplications of 16p13.3

A 16p13.3 duplication is believed to cause additional effects when more genes are duplicated. In larger duplications, people are usually more severely affected (Thienpont 2010). For a brief discussion of larger 16p13 duplications, see pages 25-26.

If your child has had a molecular genetic test, your geneticist or genetic counsellor will be able to tell you what other genes have been duplicated in your child.

Are there people with 16p13.3 duplication syndrome who are healthy and have no developmental or learning problems?

Yes. In two families, when the parents of a child with 16p13.3 duplication syndrome had their chromosomes tested, the same duplication was found in one of the parents who themselves had no learning, developmental or health problems. Since people are usually only referred to a geneticist when there is a health or developmental problem, it is quite possible that there are other people with 16p13.3 duplication syndrome who have never been tested (Thienpont 2010).

Genetic testing

Looking at chromosomes under a microscope, it may be possible to see the extra genetic material, if the piece is large enough. If the extra piece is very small, the chromosomes can look normal under a microscope. Molecular DNA technology gives a more precise understanding of the size and position of the duplication. Techniques for genetic testing that are commonly used include FISH and microarrays:

- Fluorescence *in situ* hybridisation (FISH) uses fluorescent dyes to visualise under a microscope the number of copies of small sections of chromosomes.
- Microarray comparative genomic hybridisation (array CGH) is a sensitive technique which shows gains (and losses) of tiny amounts of DNA throughout the chromosomes.

A person's chromosome make up is called his/ her karyotype. Someone with 16p13.3 duplication syndrome might have a karyotype that looks like one of these two examples:

[arr cgh 16p13.3\(RP11-75P12,RP11-95J11\)x3.ish 16p13.3\(RP11-95J11x3\)dn](#) This result tells you that array comparative genomic hybridization ([arr cgh](#)) showed that one extra copy of part of the band known as 16p13.3 was found (x3). The normal number of copies is two. An extra copy of two markers ([RP11-75P12](#) and [RP11-95J11](#)) whose position on 16p13.3 is known was found. [ish](#) shows that the analysis was confirmed by FISH, which also showed an extra copy of the RP11-J11 marker. [dn](#) de novo (Latin for 'from the beginning') means that the chromosome change has not been inherited but has arisen 'anew' ([see page 22](#)).

[arr cgh 16p13.3\(3712391-4529435\)x3](#)

This result tells you that array comparative genomic hybridization ([arr cgh](#)) showed that one extra copy of part of the band known as 16p13.3 was found (x3). [3712391-4529435](#) shows the start and end points of the extra copy, measured in base pairs. Take the first long number from the second and you find that there are 817,044 extra base pairs. This is about 817kb or about 0.82Mb. The *CREBBP* gene is found between these base pairs, so the result tells you that there is an extra copy of the *CREBBP* gene.

Larger duplications of 16p13.3

In most people, the duplication of 16p13 extends much further than the *CREBBP* gene. Features associated with a duplication of 16p13 that extends to the tip of the chromosome and can involve the entire 16p13 band overlap with many of the features of 16p13.3 duplication syndrome, but go much further. Duplication of this region has been described as a distinct syndrome, known as [trisomy 16p syndrome](#) or [dup16p syndrome](#).

Shared features

Many features associated with 16p13.3 duplication syndrome are seen in babies and children with larger duplications as well. For example, babies can have problems with the roof of the mouth, ranging from a high palate to a complete cleft of both the palate and the upper lip. They can have the typical anomalies of the hands and feet, including thumbs that are small and placed further down the wrist than normal (proximally implanted); the hands can be held in an abnormal position, as can the feet; and they can have abnormalities of the nails. Fixed, bent fingers and toes (camptodactyly), which are a sign of 16p13.3 duplication syndrome, have not yet been reported in children or adults with a larger duplication. It has been suggested that the short, underdeveloped tips of both toes and fingers seen both in children with 16p13.3 duplication syndrome and in those with larger duplications are caused by blood vessel abnormalities in the extremities.

Problems with the heart, including holes between either side of the heart (atrial septal defects or ventricular septal defects) have been reported both in the 16p13 duplication syndrome and in larger duplications, as has the more complex heart disorder tetralogy of Fallot.

A hollowed chest (pectus excavatum); spinal curvature; hernias in the groin (inguinal hernias); anomalies of the genitals in boys; hearing loss; and softening of the cartilage rings that support the windpipe (tracheomalacia) have been seen in both children with 16p13.3 duplication syndrome and those with larger duplications. Seizures have also been seen in both groups of children, but they are more common in those with a larger duplication. Children in both groups have been reported with an unusual size or formation of the broad band of nerve fibres that links the two sides (hemispheres) of the brain (the corpus callosum).

Features seen only in children and adults with larger duplications

Among the features reported only in children with a larger duplication are a double thumb; pancreatic insufficiency; unusually small corneas (the front transparent part of the eye); urinary reflux, where the urine travels back from the bladder towards the kidneys; and cystic kidneys and abnormally enlarged kidneys (hydronephrosis). In general kidney problems are more common in people with a larger 16p13.3 duplication. Having a disproportionately small head at birth (microcephaly) is also commoner in babies with large duplication, as is having a low birthweight and continuing to grow slowly, ending up as a short child and a short adult.

In terms of heart problems, vascular ring (the large blood vessel that takes blood out of the heart (aorta) or its branches encircle the tube that takes air to the lungs (trachea) and the tube that takes food to the stomach (oesophagus) and can press on them) has only been reported in those with larger duplications, as has pulmonary hypertension (raised blood pressure in the vessels that carry blood from the heart to the lungs). This finding has led to the recommendation that children with a 16p13 duplication should be

TABLE

People with tiny duplications of little more than *CREBBP* gene* Total 5

People with larger duplications including *CREBBP* gene # Total 21

Main features

Birthweights at/near term	2/5 normal birth weight	18/20 normal birth weight
Growth	4/5 normal growth	18/21 normal growth
Delay in sitting, walking etc	Walked 15 months – 2 years	Walked 17-30 months
Learning	Low normal to moderate/severe disability	Low normal to severe learning disability
Speech	3/5 Speech delay or articulation problem	15/20 Speech delay or articulation problem
Hands	4/4 various anomalies	20/21 various anomalies
Thumbs short and set lower down wrist than normal	4/5	13/21, large thumbs in one child
Incurving fingers	2/5	6/21
Webbing between fingers or toes (syndactyly)	2/5	5/21
Clenched fingers or toes (camptodactyly)	3/5	10/21
Elbows – unable to straighten/ stiff	2/5	1/21
Feet – any anomaly	4/5 various anomalies	18/21 various anomalies
Feet – position deformity	1/5	8/21
Hip anomaly	2/5	1/21
Possible autism	0/5	3/16
Behaviour difficulties	1/5 – attention deficit/hyperactive	8/19 – 5 attention deficit/hyperactive

Other features

Heart – atrial septal defect	1/5	4/16
Heart – ventricular septal defect	0/5	3/16
Heart – other	2/5: mitral valve prolapsed; dextrocardia (heart on right side of body)	3/13: Complex anomalies including Tetralogy of Fallot; pulmonary hypertension
Genital anomalies	1/4 male babies	2/13 male babies
Palate cleft/ bifid uvula	0/5	8/21
Drooping upper eyelid (ptosis)	2/5	10/21
Eyes	3/5: pale retina; short sight; strabismus (squint)	7/18: esotropia; strabismus; eye motility disturbance;
Inguinal hernias (in groin)	3/5	5/16
Kidney anomaly	1/5	0/21
Spinal anomalies	1/5 – curve & cleft in one bone in the spine	0/21
Brain anomalies	0/5	6/13 various anomalies

* Thienpont 2007; Patient 9, Thienpont 2010; Mattina 2012; Patients 1 & 2, Demeer 2013
 # Dallapiccola 2009; Patients 1-8, 11-12, Thienpont 2010; Chen 2012; Tüysüz 2012; Patients 3-9, Demeer 2013; Li 2013



What is special about your child?

“He is the sweetest, best snuggler ever! He is the strongest fighter I know.” 2 years
 “He is the most happy boy! He is loving and caring and much loved by all at home.” 3 years
 “He is ours – we love him more than anything and he loves to be loved. We take great strength from his resilient spirit and humor.” 7 years
 “ She loves everyone, gives hugs and smiles everywhere. She is loved by her family and keeps us smiling. She loves to sing and dance, loves anything pink and sparkly, and especially loves shoes! Wants new ones all the time and her favorites are high heels. Also loves to change her clothes and put on make up. Definitely a bit of a glamor girl.” 8 years
 “Quirky sense of humour. Very imaginative (which is a disadvantage as well as an advantage). Very ‘cute’ and loving in spite of all her problems and the difficulties she faces on a daily basis. Increasingly determined to overcome her problems.” 14 years

We wish we’d known ...

“I think it would have been too overwhelming for me to have found out things while I was pregnant.” 2 years
 “Nothing. This was a process that unfolded in the appropriate pace and manner. Like everyone we sought answers and insight as we began to understand our son. He remains the best resource available. We have been very fortunate to this point as we have not had to deal with heart issues/seizures etc.” 7 years
 “That everything would be OK. It is very overwhelming to get a diagnosis and scary when you don’t know anything about the diagnosis, and the doctors don’t know anything either! But we just dealt with each issue as it came up and tried to just love her and not focus on it the rest of the time. I would tell other parents to try to find time to just look at your baby, enjoy them, and not worry about what they are doing yet or not doing. Just enjoy who they are.”
 “It would have been easier if we had been able to separate her difficulties from the ‘person underneath’. It is all too easy to criticise her for doing something badly when she really can’t help it. A long term prognosis would have been very useful.”

Main features

The effects of 16p13.3 duplication syndrome depend largely on what extra DNA and genes there are. But there are still differences between people who have a similar amount of extra DNA.

- Developmental delay
- Wide range of learning ability, usually from normal to moderate difficulties
- Speech delay or difficulties
- Growth and height are typically normal
- Some joint abnormalities, typically involving feet, toes, fingers and hips
- Small, proximally implanted thumbs
- Characteristic facial features, which change with age
- Occasional behavioural problems including attention deficit and autism spectrum disorders

Less common features

- Heart problems
- Developmental problems affecting the genitals
- Defects of the palate (roof of the mouth)
- Eye and vision problems including a drooping upper eyelid and squint (strabismus)
- Inguinal hernias (in the groin)

(Dallapiccola 2009; Thienpont 2010; Mattina 2012; Demeer 2013; Li 2013)

First signs

The first signs that a baby or child may have 16p13.3 duplication syndrome are not usually noticed until after birth, although there may be non-specific signs during pregnancy. Some babies are born with obvious joint abnormalities, particularly involving the feet. Others have a cleft palate (split in the roof of the mouth). Unusual facial features, anomalies of the hands or feet, hypotonia (abnormal floppiness) or inguinal hernias, showing as lumps in the groin, may add to the picture. It is unusual for newborn babies with the syndrome to be unwell at birth, but one baby went into intensive care after a difficult delivery and others have a heart problem that may be detected on examination (Thienpont 2010; Chen 2012; Demeer 2013).

Other babies have no obvious physical signs at birth but are late to reach their developmental milestones (Unique).

“The nuchal translucency scan in week 13 of the pregnancy measured 5mm, which was outside the normal range.”

“His clubfoot was diagnosed around 20 weeks into pregnancy. We elected not to have an amniocentesis, instead using a fetal MRI which did not indicate any problems outside of the clubfoot.”

Pregnancy

Pregnancy is usually uncomplicated, although routine ultrasound scans in mid-pregnancy may reveal matters of concern, such as unusual positioning of the feet (clubfoot). In two cases there was very little amniotic fluid around the baby (oligohydramnios) (Thienpont 2010; Mattina 2012). Two mothers developed diabetes during pregnancy, in one case borderline. The umbilical cord usually contains three blood vessels, but in one pregnancy there were only two (Unique).

“Generally, lack of fetal movement.”

Also very unusually, one of the parents could be a so-called mosaic, where the duplication is present in the parent in a limited number of cells, for instance only in the sperm or egg cells. This again may cause a recurrence in a sibling. The risk is very low, but parents can opt to have prenatal diagnosis to rule out this possibility.

Your genetics centre should be able to offer counselling before you have another pregnancy and if you already have a child with the 16p13.3 duplication, prenatal diagnosis will be possible if that is what you choose.

Can my child have children of their own?

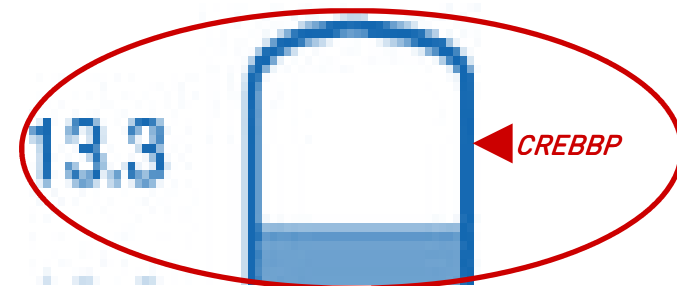
Theoretically, anyone with a 16p13.3 duplication has around a 1:2 (50 per cent) chance in each pregnancy of passing it on. In practice, it seems likely that the 16p13.3 duplication does affect fertility (Thienpont 2010).

Genes

A gene known as *CREBBP* is believed to be the critical gene that causes the symptoms of 16p13.3 duplication syndrome. The *CREBBP* gene is found between base pairs 3,775,054 and base pairs 3,930,727 in the 13.3 band of 16p. This gene provides instructions for making a protein called CREB binding protein, which regulates the activity of many different genes in different tissues of the body. CREBB protein plays a vital role in controlling cell growth and division as well as in prompting cells to mature and take on specialised functions. Animal studies suggest that CREBB protein may also be involved in laying down long-term memory. This protein appears vital for correct development before birth and afterwards.

It is believed that for correct development, just the right amount of the CREB binding protein is needed. When there is an extra copy of the *CREBBP* gene, as in 16p13.3 duplication syndrome, cells make too much of the CREB binding protein. It is believed that having too much of this protein leads to the changes seen in 16p13.3 duplication syndrome. In the opposite situation, when one copy of the gene is missing or there is a change in the gene that stops it from working properly, a different syndrome known as Rubinstein-Taybi syndrome occurs (Thienpont 2007; Thienpont 2010; Demeer 2013).

While identifying the gene(s) responsible for certain features of a 16p13 duplication is valuable and may help guide future studies, it does not lead directly to immediate improved treatment. Also, even if the supposedly responsible gene is missing, it does not always mean that the associated feature(s) will be present. Other genetic and environmental factors often have a role in determining the presence or absence of a particular feature.



features seen most often in children with a 16p13.3 duplication. A girl of 8 years has small teeth; a boy of 11 is reported to have small, crowded teeth and a small lower jaw; another boy has small teeth (Thienpont 2010; Mattina 2012; Li 2013). Unique records show a variety of concerns including overcrowding, needing orthodontic treatment; twinned teeth with large spaces between; and an unusually high number of cavities and capped teeth (Unique).

■ Puberty

Unique's experience is that puberty usually proceeds normally at the normal age. Precocious puberty is said to occur when it starts before the age of 6-8 in girls and before 9 years in boys. This has been recorded once (Thienpont 2010; Unique).

■ Other

Other problems reported in individual children include umbilical hernia (shows as an abnormal bulge that can be seen or felt at the umbilicus (belly button); underdeveloped and wrongly sited kidney; pyloric stenosis, where in a very young baby the passage between the stomach and the small intestine narrows so that feeds cannot get through (Thienpont 2010; Mattina 2012).

Why did the 16p13.3 duplication occur? Did my baby get it from me? Was it my fault?

16p13.3 duplications usually occur out of the blue for no obvious reason. Less often, they can be inherited direct either from the mother or the father. The only way to be certain is to check the chromosomes of both parents (Thienpont 2010).

If both parents have chromosomes without any relevant changes, the 16p13.3 duplication is a new occurrence. The genetic term for this is de novo (dn). A new 16p13.3 duplication has been caused by a mistake either when the parents' sperm or egg cells were formed or in the very earliest days after fertilisation. As a parent there is nothing you could have done to change or control this.

Whether the deletion is inherited or de novo, there is nothing you did as a parent to cause the 16p13.3 duplication. No environmental, dietary, workplace or lifestyle factors are known to cause these chromosome changes.

Can it happen again?

In families where both parents have been tested and have chromosomes without relevant changes, the risk of having another child with a 16p13.3 duplication is only minimally higher than anyone else's risk.

If a blood test shows that either parent has the same duplication of 16p13.3, that parent has a theoretical chance of passing it on of about 50 per cent in each pregnancy and a 50 percent chance of a pregnancy with normal chromosome 16s. In practice, however, it seems likely that the duplication affects fertility, making it less likely to be passed on. At present, however, this can only be a theory until more families with the duplication have been studied.

Very unusually, family testing shows that one of the parents carries a so-called balanced translocation. The 16p13.3 chromosomal region has switched to a different chromosome. Typically, this does not cause any manifestations. However, when the normal chromosome 16 is passed to the child, together with the chromosome carrying the other 16p13.3 region, the result is a duplication of chromosome 16p13.3.

New babies

Babies are usually a good size, born around their due date

Babies are usually born around their due date and are typically a normal weight and size. The range of birth weights at or near term was 2.3kg – 3.8kg (5lb 1oz – 8lb 6oz); the average was 2.93kg (6lb 7oz). Under a quarter of babies (5/25) were small for their gestational age (intrauterine growth retardation – IUGR) (Thienpont 2010; Chen 2012; Demeer 2013; Mattina 2012). Some babies had early breathing difficulties, in part caused by a softness in the cartilage rings supporting the windpipe or the larynx (laryngomalacia, tracheomalacia). These conditions generally improve with time and usually resolve by the age of 2. One baby suffered brain damage caused by oxygen shortage following a difficult delivery (Thienpont 2010; Chen 2012; Mattina 2012; Tüysüz 2012; Demeer 2013; Unique).

“At birth my daughter had few reflexes and was very lethargic. She was very unresponsive in every way for a long time and did not reach for a toy or rattle until she was about 8 months old. She did not respond to tickling, playing or any other stimulation other than to watch.”

“She was a reasonable size at birth and had good Apgar scores, but she was hospitalised with bronchitis at 2 months. She had to wear a special harness because of her hip dislocation which kept her legs splayed out at the side.”

“He had breathing difficulties at first and problems with breastfeeding and his weight was low. He didn't make eye contact and was easily overstimulated.”

Feeding

Newborn babies may have difficulty feeding and establishing breastfeeding may be a struggle.

Some babies have difficulty feeding, especially in the first few months. Low muscle tone may affect the face disproportionately, making it especially hard for babies to suck and swallow effectively. Establishing breastfeeding can be a struggle and babies may need to take breast milk by tube or by bottle, sometimes fitted with a specially adapted teat.

Gastro oesophageal reflux (GORD, GERD) appears to be common, where the stomach contents return up the food pipe and can cause choking, vomiting and discomfort. Reflux raises a baby's risk of inhaling food contents and setting up an infection in the lungs known as aspiration pneumonia. Reflux can be eased by careful semi-upright positioning during and after feeds, sleeping in a prescribed sleep chair rather than a bed, raising the head end of the baby's cot and if necessary by prescribed medication that helps to keep the feed within the stomach and counteract any acidity. Babies who have continuing problems can have a surgical procedure called a fundoplication to improve the action of the valve at the junction of the food pipe and stomach. In a number of children known to Unique, treating reflux has settled their long-term respiratory problems.

After the early days, Unique's experience is that feeding problems ease and by the toddler years children are eating a varied, normal diet with a wide range of tastes and textures (Dallapiccola 2009; Demeer 2013; Unique).

“At first I pumped my breast milk, and he was fed via nasogastric tube. By 1 month of age, he was able to drink from a bottle with the Haberman teat, specially made for cleft palate babies. He did great with that. He is allergic to all milk proteins and also had severe GERD, so was always elevated. We tried to treat it with Zantac (ranitidine) but that didn't work, so he had a Nissen fundoplication performed and has also had a G-Tube placed due to a swallow study showing that he has a very delayed swallow.” 2 years

"He wasn't able to breastfeed, hence infant formula from 1 month of age. He also had difficulties with choking on food and water. But today he eats everything - including things that do not taste good or are suitable as food!" 3 years

"As a newborn, he would not latch - no other issues. He had latching problems for the first 4 months and was bottle fed breast milk. He had 12 months of breastfeeding and then moved on to solid foods. By 3 years he had had 8 choking episodes in total, one necessitating hospitalisation. He has a very varied diet (Mum is a trained nutritionist) so he has appropriate amounts of healthy fat. He was fed on organic food and organic whole milk for 90% of the time over his first 30 months but more recently he has had more non-organic vegetables, although we still use organic milk.

"He now eats normally: he has a good appetite and a broad diet. He has no significant digestive problems other than an acute period of stomach upset on three separate occasions when he would begin vomiting violently 3 hours after a meal and continue for 4-6 hours. After the vomiting he would be fine. The episodes were attributed to food intolerance although no discernible pattern has been found, but we do avoid cantaloupe melon. Reflux causes ragged breathing once in a while and he has been on Prilosec [omeprazole]." 7 years

"She had a difficult time latching on to breastfeed and would have milk coming out of her nose while she fed. I was able to breastfeed. I was particular about the position I held her in while feeding her and had to be very patient with her, trying many times to get her latched on correctly. She also had severe reflux, necessitating a fundoplication at the age of five. Today she eats anything any other child would eat." 8 years

"As a newborn, she would not breastfeed and used to regurgitate standard formula milk so she had a slightly thicker formula. After the newborn period she had no further feeding problems and today she eats everything. She does have a tendency to mouth ulcers and foods such as fruit sting her mouth." 14 years

Growth and height

Growth and height are typically normal

Babies and children do not usually have any growth problems; normal growth has been reported in 22/27 individuals. One child was short following an early (precocious) puberty. It has been suggested that short stature only occurs with a larger duplication of 16p13.3 extending as far as the tip of the chromosome, but one child with one of the smallest recorded duplications was relatively short for his age and very slight at 11 years and another 5 year old boy had growth delay (Thienpont 2010; Mattina 2012; Li 2013; Unique).

"His height has fallen consistently in the 15th to 30th centile range while his weight has consistently fallen in the 40th to 50th centile range since birth. He is now 4 foot [122 cm] tall and on the 40th-50th percentile for both weight and height." 7 years

"She was able to grow and gain weight, in spite of the surgeries to correct her hips and feeding challenges. She is tall for her age and very thin." 8 years

"Average height, 158 cm [5' 2"]. " Almost 14 years

Characteristic facial features, which change with age

Many children and adults have similar facial features. Younger children typically have midface hypoplasia (the upper jaw, cheekbones and eye sockets do not grow as much as the rest of the face, so the face below the eyes looks relatively flat). Older children and adults typically have a longer face. Most typically the nose is short and upturned with small but slightly thick nostrils and a bulbous tip, and the eyes may be small or narrow

shape may flattened at the back and longer from front to back on one side than the other, so it looks like a parallelogram when viewed from on top (plagiocephaly); or it may be narrow and elongated (dolicocephaly) (Mattina 2012; Demeer 2013; Unique).

When the brain is imaged, it is usually normal. Anomalies reported in the medical literature and Unique include slightly enlarged ventricles (the fluid-filled spaces within the brain); periventricular heterotopias, where clumps (nodules) of grey matter accumulate along the walls of the ventricles; leucomalacia (white matter damage due to softening of the brain tissue); grey matter where white matter is normally; and an anomaly of the veins draining normal brain tissue in the region of the cerebellum (venous angioma). Two children are known to have a small or partly missing corpus callosum, the broad band of nerve fibres that links the two sides (hemispheres) of the brain (Thienpont 2010; Tüysüz 2012; Li 2013; Unique).

■ Epilepsy

From the information we have at present, the great majority of children with a 16p13.3 duplication do not have epilepsy. One Unique child does not behave as if she is having seizures, but her brain records seizure activity and she takes anti-epileptic medication. One child of 9 years was admitted to hospital with hepatitis and status epilepticus, where a convulsive seizure lasts for longer than 5 minutes or convulsive seizures occur one after the other with no recovery between. Another child with the 16p13.3 duplication and a change on chromosome 15 has epilepsy with different seizures types which are largely controlled by anti-epileptic medication and a seizure management infant formula (Demeer 2013; Unique).

■ General wellbeing

Unique records show that respiratory infections are common in young children and can be both persistent and severe. Six toddlers were ill enough with a respiratory infection under or around the age of 2 to spend time in hospital. In one of these children, the solution was to treat gastro-oesophageal reflux with a fundoplication, which is a surgical procedure to control acid backflow from the stomach; reflux was a factor in the respiratory infections in at least one further child. One child reported in the medical literature had tracheobronchomalacia, where the cartilage rings supporting the windpipe and airways are unusually soft, contributing to repeated lung infections. This is usually not severe and resolves by the age of 2. Two children known to Unique had laryngomalacia, a similar condition affecting the supportive structure of the voicebox (larynx) (Thienpont 2010; Unique).

Once any reflux has been controlled, and children have outgrown the recurrent respiratory infections and any surgical interventions are complete, they are generally strong and healthy.

"We make many trips to the hospital for his respiratory issues and his seizures." 2 years

"He had a 'soft' larynx, and had lung inflammation, respiratory distress and pneumonia, but today he is healthy." 3 years

"Overall he is healthy and happy." 7 years

"She is generally healthy. All of her issues are well controlled." 8 years

"Her health is OK; she has anxiety with stomach aches and wind." 14 years

■ Teeth

Dental disorders appear to be more common among children with a chromosome disorder than among typically developing children. Small or overcrowded teeth are the

reported in the medical literature and in 4/7 Unique children (Thienpont 2010; Tüysüz 2012; Demeer 2013; Unique).

Other eye problems include a disturbance in the normal movement of the eyes; long and short sight; and astigmatism, where the cornea at the front of the eye is abnormally curved. Four/7 Unique children wear glasses or have done so in the past (Thienpont 2010; Demeer 2013; Unique).

Blockage of the tear duct that drains fluid from the surface of the eye to the back of the nose has also been reported. This is a common problem in babies, and usually clears on its own. At least one child with a 16p13.3 duplication has needed a small surgical operation to open up their tear ducts (Thienpont 2010; Demeer 2013; Unique).

■ Inguinal hernias

While most babies and children are unaffected, almost one third – 8/26 in the medical literature and 2/7 at Unique – have an inguinal hernia. This shows as a bulge in the area where the lower abdomen meets the upper thigh (the groin) and may be seen on one side or both. The cause is that an opening in the lower part of the wall of the abdomen that is open during fetal life fails to close as normal before birth. The remaining opening may be small, only allowing fluid through, or it may be large enough for something such as a loop of the intestine or another organ to get stuck in it. An inguinal hernia should always be assessed by your child's doctors and your child may need surgery to repair it. Of the cases reported in the medical literature, in one baby the hernia was strangulated (the blood supply to the intestine was cut off), requiring emergency surgery at 8 months. Another baby had the hernia repaired at 1 year (Thienpont 2010; Mattina 2012; Demeer 2013; Li 2013; Unique).

Other concerns

■ Hearing

A hearing defect has only been reported twice. One child with very small ear canals had a mild permanent hearing loss in one ear and a moderate-to-severe loss in the other ear. Another child has mild hearing loss in both ears and wears hearing aids. A temporary type of hearing loss known as glue ear is very common in all young children. It is relieved by draining fluid from the space behind the ear drum, and sometimes by inserting tiny plastic aeration tubes (grommets) into the eardrum itself (Demeer 2013; Unique).

■ Body and spine

Pectus excavatum, where the chest is hollowed and the breastbone depressed, has been reported in 7 children. The chest may also be asymmetrical. Pectus excavatum can be mild or so obvious that it can affect cardiac and respiratory function and cause pain in the chest and back, but Unique families report no problems with it.

In one child some of the spine bones (vertebrae) were joined together; another child had a split in part of a bone at the lower end of the spine. Two children have a spinal curvature; one has a fatty lump overlying the spine; two others have a dimple at the base of the spine (Dallapiccola 2009; Thienpont 2010; Mattina 2012; Demeer 2013; Unique).

“The pectus excavatum is mild so it has no real impact yet.” – 8 years

■ Head and brain

Most children's heads are a normal shape and size, but a few children have an unusually sized or shaped head. It may be very small (microcephaly) or large (macrocephaly). The

and slant upwards. The upper eyelid may droop so the eye is not fully open (ptosis). If necessary, the eyelid droop can be corrected by surgery. The upper lip between nose and mouth is typically long and the upper lip is often thin. The ears typically stick out and are set lower on the head than normal; they may be cupped, tilted backwards or have an unusual shape. Other facial features observed include a high, narrow forehead; sparse eyebrows; skinfolds across the inner corners of the eye; a small lower jaw; and fine, blonde or in one case red hair. Some children have facial hypotonia, so the muscles of the face have a markedly low tone, giving their face an unusually still, expressionless appearance (Marangi 2008; Thienpont 2010; Mattina 2012; Tüysüz 2012; Demeer 2013; Li 2013; Unique).

Dribbling (drooling), probably caused by low muscle tone in the face, has been reported. Some children outgrow this, but if not, it can be treated. As well as hyoscine patches, a medicine called glycopyrrolate can be given by mouth. The salivary ducts at the bottom of the mouth can be tied off so saliva still comes from the top of the mouth but not the bottom (Thienpont 2010; Mattina 2012; Unique).

“My daughter has somewhat droopy eyelids, especially on the right, but not enough for an official diagnosis of ptosis. She also had limited facial movement in her forehead and cheeks but used her eyes and mouth very well to express emotions.”

Development

Expect some delay – but the range is very broad

Some degree of developmental delay can be expected. Some babies appear to develop within normal limits during their first year, while in others there is obvious delay from early on. Among Unique families, delay was first noticed between the ages of six months and 2½ years (Mattina 2012; Demeer 2013; Unique).

“He was up to par with his development until he was 8 months old. It was at that time we noticed he started having seizures, and infantile spasms. He is globally developmentally delayed.” 2 years

“He was noted not to be on track in gross motor skill development by 9 months. Through many evaluations he was determined to have a 35% delay at 37 months. He is significantly delayed compared with same age peers at 7 years.”

“We noticed it at around 6 months when she wasn't progressing past the newborn stage. She is still delayed, mostly a bit immature for her age. Socially, she doesn't always read cues from other children. She will sometimes hit or take things from others. She will yell what she wants to say. Her best friends are kids who are around 2-3 years younger than her.” 8 years

“We first noticed the delay in walking at 2½ years. She was slightly later than expected for speaking. Today she is slower and less coordinated than other children of her age.” 14 years

What do children enjoy?

Playing with his cars. But his play is very stereotyped. He likes TV. 3 years

Most enjoys wrestling, iPad (games and children's shows), Wii (games), animals, swimming. 7 years

She likes to swing and she loves her ballet class. 8 years

Most enjoys swimming, ski-ing. Favourite activities are reading, writing, computer. 14 years

Sitting, standing, walking

Many babies hold their head up, sit, stand, move and walk late

Babies and children with 16p13.3 duplication syndrome typically face delay in reaching their mobility milestones but the extent of the delay is extremely varied. Some children show no delay in gross motor skills and sit up and walk at the expected age for a typically developing child. Part of the difference between individual babies is due to underlying health problems, such as heart conditions, and part also due to features such as feet or dislocated hips that need surgical correction before walking becomes possible. Many babies also have low muscle tone but with maturity and physiotherapy, this generally improves.

Joints can be hypermobile and children may need support in the form of splints, supporting boots, standers or walkers, to become mobile.

Babies in this group learned to roll over between the ages of 5 and 8 months and were able to sit up between 8 and 14 months. Babies became mobile between 16 months and just after their second birthday. The earliest walkers were on their feet around their first birthday, and walking independently between 15 months and 4 years. Some Unique families reported that their child had an unusual or unsteady walking style, and that this was more obvious when running, when they could wobble and fall.

Early intervention and physiotherapy are important for children showing significant delay. Most children at Unique have low muscle tone (hypotonia) which is a major contributor to their difficulty in sitting up unsupported and learning to walk. Two children are reported to have unusually lax joints, which also contributes to delay in mobility (Dallapiccola 2009; Thienpont 2010; Chen 2012; Mattina 2012; Tüysüz 2012; Demeer 2013; Unique).

"He loves to snuggle with me." 2 years

"He is always in motion, even at the table, and most enjoys jumping on the trampoline. He generally seems very stiff in his body, but this is supposedly due to his low muscle tone." 3 years

"He walks with a considerable limp due to his clubfoot, and does not run very frequently. His physical delays have been attributed to hypotonia and the low muscle tone has affected his development in a very significant way. He has only recently started to jump without a trampoline (he can now jump about one inch off the floor), and runs very infrequently and slowly. His joints are borderline hyperlax, but the low muscle tone has far greater impact. He most enjoys wrestling, chasing chickens, and swimming." 7 years

"She is walking well now holding a hand, and has been able to run since she was 4. Her gait is not normal, but she is very functional. Her lax joints don't seem to affect her mobility and her low tone means that she gets tired quicker than other kids. Otherwise she functions normally. She likes to swing and loves her ballet class." 8 years

"She moves around OK, but hypotonia makes her slow and clumsy. She most enjoys swimming and ski-ing." 14 years

Using their hands: fine motor and co-ordination skills

Abilities are very varied

Information from Unique shows that children's fine motor abilities are extremely varied. Hand and eye co-ordination skills such as holding and playing with small toys and holding implements such as cutlery and writing implements does not necessarily develop in line with gross motor skills. Some children are dexterous and well coordinated; others find gripping and grasping difficult and unrewarding. Children with weak hands or very flexible joints in their hands find holding objects especially difficult. Early intervention

testes are a fairly common occurrence. If the testes do not descend into the scrotum of their own accord, they can be brought down and fixed in a minor surgical procedure. In a further boy, the testes had taken an unusual route and ended up in an unusual position. This boy and one other were born with hypospadias, where the hole normally situated at the end of the penis is on the underside instead. This can be corrected surgically.

The second boy with hypospadias also had what is known as shawl scrotum, where the scrotum surrounds the penis instead of lying behind it (Thienpont 2010; Mattina 2012; Demeer 2013; Unique).

"He had a surgery for undescended testicle in his first year." 7 years

"The lips hang down quite a lot which used to be quite uncomfortable for her. It's better now that she has more pubic hair." 14 years

■ Defects of the palate (roof of the mouth)

In the developing fetus, the palate fuses at around 12 weeks from pieces that start on opposite sides of the head. A cleft occurs when the pieces come round but do not join. Defects in the roof of the mouth (palate) are common in children with and without a chromosome disorder. The hard palate at the front of the mouth may be split but more typically the split is found further back in the soft, fleshy tissue at the back of the top of the mouth. Occasionally the split is only seen in the tissue that hangs down above the tongue at the very back of the mouth (uvula, known as a bifid uvula when it is split). A cleft palate causes difficulties both in feeding and in speech production. Surgical repair of the palate eases these difficulties and may eliminate them altogether.

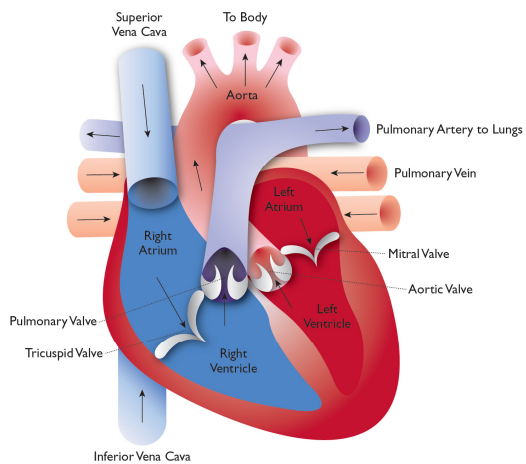
A cleft or other anomaly has been found in 8/26 babies or children reported in the medical literature, and as a cleft in the soft palate at the back of the mouth in 2/6 in the Unique survey. One baby had a complete cleft palate and upper lip; two had a split uvula. In two further children the palate was unusually high (Thienpont 2010; Mattina 2012; Tüysüz 2012; Demeer 2013; Unique).

■ Eye and vision problems including a drooping upper eyelid and squint (strabismus)

The most common concerns are ptosis and strabismus

A common feature of the eyes in a child with 16p13.3 duplication syndrome is ptosis. The upper eyelid of one eye or both droops; the droop may only be slight, so you hardly notice it; or it can obscure vision and require surgical correction. 12/26 children reported in the medical literature are affected by ptosis, including the child with the smallest duplication including only the *CREBBP* gene and part of the *ADCY9* gene only. Babies with ptosis are regularly checked to ensure that vision is not affected. If there is any risk that vision will be affected, surgical correction will be considered. This usually involves shortening the muscles that raise the eyelid or helping to raise the eyelid by inserting a sling of material between the forehead and the eyelid.

Strabismus, the medical term for squint or crossed eyes, can occur with ptosis or without. The crossed eye can look inwards, outwards, up or down. The main effects of strabismus are that the person will usually have one eye which is stronger than the other. This is because the brain has to give priority to one eye over the other with the result that the weaker one does not "learn" to see as well as the stronger one. Treatment of strabismus depends on the cause but can include patching the stronger eye, exercises, glasses to correct a refractive error such as long sight and surgery to realign the muscles that hold the eye in place. Strabismus has been reported in 6/26 children



A normal heart

blood pressure in the pulmonary artery (pulmonary hypertension). High blood flow to the lungs can make a baby breathless and the heart muscle enlarges because it has to work harder than normal. Untreated pulmonary hypertension can cause serious lung damage. Treatment depends on the individual case but can include medication to help breathing; monitoring to see if the VSD gets smaller or closes on its own; surgery to close the VSD; and in some cases pulmonary artery banding to narrow the pulmonary artery and reduce the high blood flow to the lungs.

Other heart problems have each been seen in only one child. One baby was

born with an ASD, a VSD and leaky valves between the atriums and ventricles; another with tetralogy of Fallot, a complex abnormality consisting of two main problems: the pulmonary valve that regulates blood leaving the heart for the lungs is narrow (pulmonary stenosis) and there is a large hole between the right and left ventricles, the lower pumping chambers. This means that less blood flows through to the lungs and the level of oxygen in the blood is low. Tetralogy of Fallot is corrected in a surgical operation. Another child had a mitral valve prolapse, where the flaps of the mitral valve that controls the flow of oxygenated blood from the collecting chamber to the pumping chamber do not close tightly and are floppy, allowing blood to leak the wrong way through the valve. A further child (see below) was born with an ASD, VSD and persistent ductus arteriosus (PDA), where a channel between the aorta and the pulmonary artery that takes blood to the lungs stays open instead of closing shortly after birth. When it stays open, the lungs receive more blood than they should and the heart has to work too hard.

In a further child the heart was positioned on the right of the body, instead of the left (dextrocardia). One child had a structurally normal heart, but with an enlargement of a channel that leads from the aorta - taking blood away from the heart to the rest of the body - to the left coronary artery, which brings oxygenated blood to the heart muscle (dilatation of sinus of Valsalva) (Thienpont 2010; Mattina 2012; Demeer 2013; Li 2013; Unique).

“He had an ASD, a VSD and persistent ductus arteriosus at birth, but they all closed up on their own within 6 months.” 2 years

“Abnormal heart structure, but normal functioning.” 3 years

■ Developmental problems affecting the genitals

Minor anomalies of the genitals and reproductive system appear to be somewhat more common among babies and children with a chromosome change than among others, and this is true of those with 16p13.3 duplication syndrome. However, most babies are born with normal genitals. Among the 17 males reported in the medical literature, two were born with undescended testes, and this has also been seen at Unique. Undescended



7 years

with play and occupational therapy to stimulate hand use is almost always very helpful, and parents recommend keyboards and toys with lights and music for early skills and stringing beads and cards for more advanced development. This range of skills impacts on children’s ability to feed themselves, to use a spoon and fork, to dress and wash, and later to use an implement such as a pencil for drawing and writing. Children who have mastered play skills well and on time may still remain clumsy and need support from occupational therapy for handwriting (Marangi 2008; Unique).

“Overall his fine motor skills are poor.” 3 years

“He has long fingers but this has no impact on his fine motor skills. His drawing is illegible and this is very frustrating for him. The low muscle tone in his hands is severely limiting. He uses an iPad & Wii – but fine motor skill is very difficult to motivate through frustration.” 7 years

“She struggled with letting go of objects to eat when she was 18 months. At 8 years she can write and draw very well and feeds herself completely. She has good fine motor skills.”

“Her pencil hold is a bit strange but she has had OT since around the age of 2 and still has it once a week, so these skills have improved considerably. Her writing is OK now.” 14 years

Personal care and toilet training

Daily tasks like getting dressed and undressed, washing and brushing teeth will also be difficult, although using stretchy clothes, Velcro fastenings and slip-on shoes helps. Children gradually progress with daily repetition, cues, prompts, reminders, laying out clothes, recognised routine and bribery but, as ever, some get very much further than others. Children’s ability with personal care directly reflects their fine motor skills and the enjoyment they take in the activity. There is an enormous range of ability, with some

children needing little more than gentle reminders, while others are almost totally dependent.

Typically, children use their hands for eating, graduating late to toddler cutlery, and many needing special easy grip implements. Even with these, they may drop food liberally or throw it rather than feed themselves.

Toilet training has been achieved in the daytime between 2 and 6 years, but a 7-year-old boy was not yet dry in the daytime, and a 14 year old boy was not yet dry at night (Demeer 2013; Unique).

"He is not independent – we are still working on dressing, washing and toileting. Personal care is our biggest frustration as parents. He does not have the coordination or muscle strength or motor planning to dress and undress himself. He is not yet completely toilet trained – he will ask to defecate but not to urinate so we need to initiate bathroom trips. But he was dry overnight by 3." 7 years

"She is completely independent with potty issues, bathing, washing, even fixing her hair. She was dry in the day from the age of 4 and at night two months later." 8 years

"Her personal care is OK but not perfect." 14 years

Learning

A wide range, usually from normal to moderate difficulties

Children with the 16p13.3 duplication syndrome are likely to need some support with their learning, although the extent varies widely from child to child. Evidence from the medical literature and from Unique families shows a very scattered pattern, with great variation in learning strengths and weaknesses and in the skills achieved. Overall, out of 20 school age children and adults, four do not have a diagnosis of learning difficulty or disability; one is considered to have a mild learning disability; in two it is mild-to-moderate; in 10 moderate; in two moderate-to-severe; and in one, severe (Marangi 2008; Dallapiccola 2009; Thienpont 2010; Chen 2012; Mattina 2012; Tüysüz 2012; Demeer 2013; Li 2013; Unique). Where a child's IQ (intelligence quotient) has been measured, scores given in the medical literature range between 35 and 65. IQ tests show inconsistent strengths and weaknesses: in some children performance outpaces language; in others, language skills are strongest, and children struggle with mathematical skills.

Learning strengths noted by Unique families include determination to succeed and a desire to please; some children have a good memory, but this is not a consistent feature. Learning areas where children are likely to need extra support are impulsivity, focus and concentration, and at least one family is considering using medication to improve their child's concentration. Some children also have a specific weakness in hand control. Others have a specific weakness in particular subject areas, such as mathematics. Most children attend schools where they can receive special education for part of the day, joining their same-age peers for the rest of the time. Unique families say that what helps their child most is 1:1 extra targeted support and one child made very considerable progress at a school where she received targeted learning.

"He is about 1 – 1½ years behind children his age but is very good at imitating other children. He has great difficulty maintaining attention and great difficulty in excluding stimuli." 3 years

"We are still trying to understand what our expectations should be. Language and letters seem to be his strength, math and problem solving are significant weaknesses. He is not yet reading – give us another year and he will read basic sentences. He can draw large circles with significant effort. Has an IEP. Attends public school in a special education

unassisted. At the age of 3, she had a bilateral pelvic osteotomy and left femoral osteotomy, followed by 2½ months in a hip spica. She can walk and run now. Her gait is not normal, but is very functional." 8 years

"Our daughter wore a harness that kept her legs out at the side, but we suspect that this caused necrosis of the hip joint as one leg became longer than the other and she had to have a knee operation to remove the growth plate in one leg." 14 years

Hands

The hands of a child with 16p13.3 duplication syndrome may be slightly unusual: the most typical feature, seen in 17/26 people, is thumbs that are set unusually close to the wrist (proximally implanted) and are usually small. Additionally, the fingers may be long and tapering (7/25), sometimes with short or cone-shaped tips. One or more fingers may be clenched or bent (camptodactyly) and one or more may curve inwards (clinodactyly). The fifth finger may be unusually short. The nails may be unusually curved or underdeveloped and there may be no crease between the middle and end finger joints. Occasionally two or more fingers may be joined by a web of skin (syndactyly) (Dallapiccola 2009; Thienpont 2010; Mattina 2012; Tüysüz 2012; Demeer 2013; Li 2013; Unique).

"The splints they used on his hands worked wonders to bring his fingers out, he now has 80% use of each hand! His thumbs don't come out completely." 2 years

"His fingers look a little bit different, but it doesn't affect his function." 3 years

"He has long fingers, but this has no impact. However the low muscle tone in his hands is severely limiting. Drawing is illegible for him and very frustrating." 7 years

"Her fingers are very long and tapered; her hands are larger than mine. It doesn't seem to impact her use of them." 8 years

"Her thumbs are positioned a little strangely. When she has her hands on the floor, she doesn't put them flat; the thumbs curl inwards." 14 years

Elbows

An inability to fully open the elbows so the arms are straight has been seen in a few children with 16p13.3 duplication syndrome. The elbows may also seem stiff (Dallapiccola 2009; Thienpont 2007; Thienpont 2010; Mattina 2012; Unique).

"She doesn't fully extend her arms when she is walking, she keeps them bent a bit."

8 years

"She cannot straighten her arms." 14 years

■ Heart problems

Both minor, self healing problems and complex anomalies are found

Although most babies with 16p13.3 duplication syndrome are born with strong, healthy hearts, defects in the structure of the heart are seen fairly commonly. The problems range from ones that self-correct in time and have little or no impact on a child's health or functioning to major, complex ones that need surgical correction.

Six/21 babies were born with a septal defect, that is, a hole either between the atriums, the upper collecting chambers of the heart (atrial septal defect, ASD) or between the ventricles, the lower pumping chambers (ventricular septal defect, VSD). An ASD can be small, causing no problems and not needing treatment. A large ASD can mean that the right side of the heart receives too much blood, causing a build-up of blood which in the long term can damage the heart and sometimes the lungs. An ASD can be closed either by keyhole or open heart surgery. A large VSD means that some of the blood that should have gone to the rest of the body goes instead to the lungs. A large VSD also causes high

points up. The bottom of the foot is stiff and has no arch; it usually curves out, often described as 'rocker bottom'. Five babies had a valgus anomaly of the feet. A valgus abnormality means that the foot is turned outwards. Four babies had a type of clubfoot known as talus valgus, and five had a positional anomaly known as claw foot or pes cavus, in which the arch is very high and doesn't flatten on weightbearing. One boy was born with an anomaly known as pes calcaneovalgus, in which the heel points down and the foot is turned outwards and developed claw foot when he was 11 years old.

The approach to positional foot anomalies depends on the severity and whether the foot can be manipulated. Some anomalies can be corrected with physiotherapy, splinting or the Ponseti method, where the foot is gently manipulated to gradually reduce the bend. The foot is held in its new position after each correction in a plaster cast. Most babies will also need the Achilles tendon to be released. This is a minor procedure that is performed under a local anaesthetic. Once the foot bend is completely corrected, the child wears special boots attached to a bar to maintain the new position. Sometimes surgery is needed to correct the bend in the foot.

Other unusual features affecting the feet include clenched toes (camptodactyly), seen in eight/26 children; an unusual big toe (short, stubby, large or turned outwards), seen in 5 children; a 'sandal gap', where there is a space between the big and second toes, seen in 6 children; and toes joined by a web of skin or tissue (syndactyly), seen in 4 children. One child had incurving toes (clinodactyly); another had small feet and pigeon toes, pointing inwards (metatarsus varus); others have overlapping toes. Seven children have unusual nails, most commonly deeply curved, but one child had no nails on the big toes until the age of 18 months (Dallapiccola 2009; Thienpont 2010; Chen 2012; Mattina 2012; Demeer 2013; Li 2013; Unique)

"He was born with left talipes and his foot was corrected over the first year by the Ponseti method plus two surgeries. However, he walks with a significant limp." 7 years

"She had a right clubfoot. It was treated with Ponseti casting at 2 weeks and required a tendon transfer surgery when she was 5. Now it is very functional. It never seemed to impact her mobility." 8 years

"She has hallux valgus which looks like a kind of bunion on her big toe, plus the middle toe curls under the next toe. Recently her left foot has started to point inwards a lot and she appears to drag her foot a bit. We have difficulty in buying shoes with her toes bulging out, and sometimes it is painful to walk with her middle toes curling under." 14 years

Hips

Two/26 babies were born with dislocated hips and another baby has asymmetrical thigh bones, with a wide angle on the right. Two further babies have coxa valga, a hip deformity characterised by increased angle between head of femur and its shaft. Babies are routinely checked at birth for dislocated hips. Treatment depends on the individual case but aims to stabilise the head of the thigh bone in the hip socket using a splint, harness or special plaster cast (hip spica). Surgery is sometimes needed to position the hip correctly by loosening tendons around the hip (an open reduction) and anything preventing the hip from moving properly. Sometimes the bone needs reshaping (osteotomy) (Thienpont 2010; Mattina 2012; Unique).

"She was born with hip dislocation and the heads of her femurs above the hip sockets. She could not move her legs at the hip joint. They were stiff and her legs were rotated outwards so the feet pointed out instead of straight ahead. She had an open reduction at 8 months, came out of the hip spica at 14 months and within two weeks was sitting

classroom and attends the regular education classroom for an hour or two per day."

7 years

"My daughter is going into 2nd grade, but didn't receive passing grades in 1st grade. So she is probably about kindergarten level or the start of 1st grade. What helps her learning is that she is determined and doesn't seem to get bored repeating the same activity multiple times. She struggles with staying focused but the teacher just re-directs her. She also struggles with getting frustrated when she can't do something, so they give her a break and try again later. She has a very poor memory, and loses things all the time because she doesn't remember where they are. You can tell her something and ask her to repeat it back, and she will not remember what you said. She is reading books for beginners. She can write the alphabet and copy words." 8 years

"On a recent test, my daughter was average on the WISC (Wechsler Intelligence Scale for Children) but has been low average in the past. She spent the last 2 years at a special school where targeted learning helped her to make huge progress. She is average at English, and her writing and spelling are good, but behind in maths which she finds hard as she does conceptual learning. Her thinking is a bit disorganised. She wishes to please, and loves writing, so wants to do this all the time but doesn't like to plan her stories. She loves reading adventures and romance stories and has read Harry Potter books, the Hunger Games, Percy Jackson, Enid Blyton and many others. She sometimes has phases of not finishing books if she can't follow the plot. (Her technical ability to read is better than her understanding). She has written hundreds of stories, but most of them are unfinished! She used to attend a special school as a boarder and extra targeted support on a 1:1 basis was ideal for her. Her latest WISC assessment showed an improvement of over 20 points in IQ in 2 years." 14 years

Speech and communication

Many children start speaking late. They have difficulty saying some sounds.

Speech delay or difficulty appears to be a hallmark of the 16p13.3 duplication syndrome. Out of 24 children, 18 had a specific speech delay or difficulty saying certain words or sounds. An 18-month-old child spoke fewer than 5 words; one 22-month-old had a vocabulary of 3 words, while another child of the same age had a greater delay in understanding than in talking; a 2½-year-old had a vocabulary of less than 10 words; one 3-year-old was not yet talking, while another child started talking at 3 years; a four-year-old used occasional single words, but relied mostly on signing and understood better than he talked; a 5-year-old could say a few words, but they were partly incomprehensible; a 6-year-old had a small vocabulary of 10 words and no sentences; a 12-year-old had a vocabulary of only a few words; a 13-year-old had a marked speech delay; and a 14-year-old used no speech.

However, not all children are affected. One child of 3 years who was babbling at 6-7 months and talking at 14 months had a usable vocabulary of 350-400 words and was able to make simple requests. By the age of 7, he was speaking in simple sentences and grasping simple humour and teasing, able to hold an almost fluent conversation of four or five exchanges before his concentration faltered.

Some children have difficulty making the sounds of speech. A 3-year-old speaks fluently, but has pronunciation difficulties and misses the ends of words. A 5-year-old girl spoke a few words, but they were 'partly incomprehensible. Two children, aged 4 and 16 years, each had severe verbal dyspraxia. Verbal dyspraxia is a condition where children have difficulty making and coordinating the movements needed to produce clear speech.

Children find it hard to produce speech sounds and put them together in the right order. Their speech is hard to understand and sounds unusual. An 8-year-old and an 18-year-old also had speech articulation problems. A 7-year-old has a very nasal voice and tends to shorten words and sounds.

Where children have been formally tested, the speech has scored between 74 and 39 at 3 to 16 years. In the 16-year-old, a severe expressive language impairment was obvious by his second year. He used few words but wanted to communicate and used gestures instead. His speech was limited to a few short sentences and there was a marked discrepancy between his performance and verbal IQ test results.

(Marangi 2008; Dallapiccola 2009; Thienpont 2010; Chen 2012; Tüysüz 2012; Demeer 2013; Li 2013; Unique)

"He didn't babble, but he said the word *Momma* at 4 months. He still only says one word, and doesn't try to say anything else, but he can express his feelings, if he's mad, hungry, sad, or hurting with certain sounds that I notice." 2 years

"His babbling was very limited; his first words came around 1½ years old. Now he is almost fluent, but has difficulties in pronunciation, especially the endings of words."

3 years

"We are very focused on him. What he can't communicate in words we can read in body language. This is a bit of a problem with therapists/educators as they try to help us determine what is learned helplessness and what are true limitations. His cousins, social stimulus and reading books all help." 7 years

"She started to smile occasionally when she was about 9 months old. Today she communicates by using a lot of body language, pointing, showing, some signing, and she speaks. Her speech is limited by her vocabulary but she is mostly verbal. Her conversation is fluent, but more like a 5-6 year old's than an 8 year old's. She understands almost anything you say, but has a difficult time finding the words to use when she wants to communicate. She can identify an animal if you give her a picture of many animals and say 'Point to the'. But if you point to a specific animal and say 'What is this?' she won't know the name of it. She has difficulties with the *th*, *g*, *s* and *r* sounds, When she was younger sign language was great, now she is mostly verbal." 8 years

"She does have social communication difficulties. She first started talking around the age of 2 and now uses everyday speech and fluent conversation. But she doesn't always understand inferences and jokes and can take things literally. Previously some letters were not clear: she would say *n* instead of *l*, but that is OK now. She has speech therapy once a week, and a social communication group class." 14 years

Behaviour

Many children have no behavioural problems but difficulty concentrating is common and a few children have an autism spectrum disorder

Many children have no behaviour problems, but a substantial minority do. Nine children/24 have difficult behaviour and in one adolescent the marked behaviour difficulties were the reason he had a genetic test. Six children have been diagnosed with attention deficit hyperactivity disorder and other families mention the difficulties their child has in concentrating. Four children have been diagnosed with an autism spectrum disorder. Fits of anger, aggression, destructive behaviour and temper tantrums have been seen in three children and inappropriate social behaviour in one adolescent, although social interaction was a strength in other children. One child had a tendency to invent untrue stories when not engaged in social interaction. Behaviour difficulties can

start early, in one child when she started nursery. They have been seen in children of all ages up to 18 years (Marangi 2008; Thienpont 2010; Demeer 2013; Li 2013; Unique). This relatively high rate of difficult behaviour means that families should be alert to early signs and be able to call on supportive behaviour management services.

"He is usually quiet or sleeping, as long as he is fed on time and given his medicines on time. He does grind his teeth, and has many repetitive movements, and lack of eye contact." 2 years

"He is a very happy and smiley boy, but he has been diagnosed with autistic-like behaviour. He plays happily but rigidly and stereotypically with his favourite toys, which are cars. He is also repetitive and has difficulty switching contexts. Socially, he lacks personal boundaries, and has difficulty 'reading' other children. Other difficulties are hyperactivity, sensory seeking, and lack of concentration." 3 years

"He is a good child and has very few outbursts but lack of concentration is our biggest concern and we are currently struggling with the question of medication for concentration issues. We have not had any discussions regarding autism with the medical community. Socially, he holds his own – social interactions seem to be a strength at this point." 7 years

"She has issues with hitting other children. She would say she was playing and didn't understand why she was in trouble. She struggles with focusing on one task for any length of time and really struggles with whole group activities, mainly playing during them. Socially, she doesn't always read cues from other children. She will sometimes hit or take things from others. She will yell what she wants to say. Her best friends are kids who are around 2-3 years younger than her. She loves everyone, but doesn't understand personal space. She gets in people's faces, hugs strangers, pats people on the stomach. She loves everyone, but can get angry or frustrated when that love isn't returned." 8 years

"Her social skills are not good compared to her peers and she has become very anxious. She hasn't been diagnosed with a disorder, just has anxiety with obsessive compulsive disorder and obsessive thoughts. She is now starting to receive cognitive behavioural therapy for this. She was checked recently and apparently is not autistic but she does show autistic tendencies. Socially, she has difficulty keeping friendships. She is very sociable but doesn't understand social situations very well and has a tendency to talk constantly about her favourite subject: films and celebrities. She has just started to take a homeopathic remedy to help her relax." 14 years

"Her social skills are not good compared to her peers and she has become very anxious.

She hasn't been diagnosed with a disorder, just has anxiety with obsessive compulsive disorder and obsessive thoughts. She is now starting to receive cognitive behavioural therapy for this. She was checked recently and apparently is not autistic but she does show autistic tendencies. Socially, she has difficulty keeping friendships. She is very sociable but doesn't understand social situations very well and has a tendency to talk constantly about her favourite subject: films and celebrities. She has just started to take a homeopathic remedy to help her relax." 14 years

Sleep

Unique members report no consistent pattern of sleep difficulties, although babies and children who had to sleep in a leg brace to correct an abnormal foot position slept more restlessly. One girl takes diazepam to help her sleep, while another is trying behavioural methods to relieve anxiety that makes settling difficult (Unique).

Typical features

■ Some joint abnormalities

Typically some joints develop abnormally. Some abnormalities are obvious at birth; others are only discovered on investigation. The toes, feet, hips, fingers and elbows are most often affected. Most children will receive regular physiotherapy.

Feet

Nine/ 26 babies were born with a positional abnormality of one or both feet. One baby was born with a condition known as vertical talus. The talus bone in the ankle has formed in the wrong position and other foot bones have moved on top of it. As a result the front of the foot