Inform Network Support

Rare Chromosome Disorder Support Group
G1, The Stables, Station Road West, Oxted, Surrey RH8 9EE, United Kingdom
Tel: +44(0)1883 723356
info@rarechromo.org | www.rarechromo.org

Join Unique for family links, information and support.

Unique is a charity without government funding, existing entirely on donations and grants. If you can, please make a donation via our website at www.rarechromo.org Please help us to help you!

Websites, Facebook groups

http://pkskids.net
http://pkskids.ning.com
www.pks.org.au
www.pksitalia.org
www.facebook.com/pages/Pallister-Killian-Syndrome-PKS
www.facebook.com/pages/Sindrome-Pallister-Killian (in Spanish)

Unique mentions other organisations' message boards and websites to help families looking for information. This does not imply that we endorse their content or have any responsibility for it.
This information guide is not a substitute for personal medical advice. Families should consult a medically qualified clinician in all matters relating to genetic diagnosis, management and health. Information on genetic changes is a very fast-moving field and while the information in this guide is believed to be the best available at the time of publication, some facts may later change. Unique does its best to keep abreast of changing information and to review its published guides as needed. This booklet was compiled by Unique and reviewed by Dr Michel Vekemans, Department of Genetics, Hopital Necker Enfants Malades, Paris, France 2004 and by Unique's chief medical advisor, Professor Maj Hultén, Professor of Reproductive Genetics, University of Warwick, UK. 2005 (PM). This booklet was updated by Unique in 2016 (AP) and reviewed by Dr Moira Blyth, Consultant in Clinical Genetics, Chapel Allerton Hospital, Leeds, UK.

Copyright © Unique 2016

Rare Chromosome Disorder Support Group Charity Number 1110661
Registered in England and Wales Company Number 5460413

Understanding chromosome disorders
Unique

Pallister-Killian syndrome

rarechromo.org

Pallister-Killian Syndrome

Pallister-Killian syndrome is caused by the presence of a small extra chromosome in some cells of the body. The extra chromosome is made up of two mirror copies of the short (p) arm of chromosome 12. This type of chromosome is called an isochromosome. Cells usually have two copies of chromosome 12, each containing a 'p' and a 'q' arm. The addition of two more 'p' arms of chromosome 12 results in cells having four copies of this part of chromosome 12 instead of two. This is referred to as mosaic tetrasomy 12p. Mosaic means that the extra chromosome is not found in all cells and tetrasomy means that there are four copies as shown in the image below.

Cells with tetrasomy 12p have two copies of chromosome 12 and an extra isochromosome made from two opposite facing p arms of chromosome 12

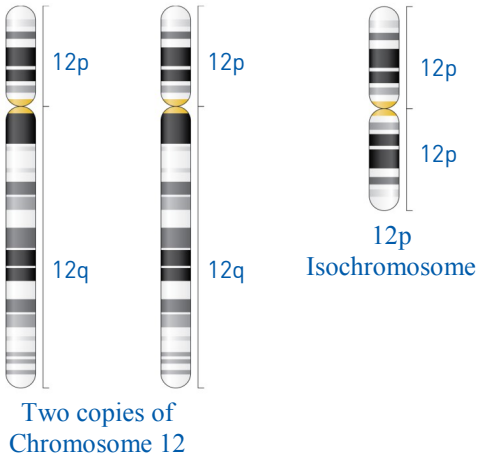

The effects of mosaic tetrasomy 12p are caused by the genes carried on the extra chromosome. Typically, these genes cause a distinctive syndrome called Pallister-Killian Syndrome (PKS). However, for reasons that are not well understood, the severity of the effects of having mosaic tetrasomy 12p varies enormously between people. Therefore, not all children diagnosed as having mosaic tetrasomy 12p will have classical Pallister-Killian Syndrome. Only those who are recognisably affected by the extra DNA are described as having classical PKS and these are the children who will be considered in this booklet.

Sources

The information in this booklet is drawn from published medical literature and information from Unique members. The first-named author and publication date from articles in the medical literature are given to allow you to look for the abstracts or original articles on the internet in PubMed (http://www.ncbi.nlm.nih.gov/pubmed). If you wish, you can obtain most articles from Unique. Unique member surveys were carried out in 2004 and 2016. In addition to this, Unique held an international study weekend in 2010. Please read our Pallister-Killian Syndrome Study Weekend Report available on our Disorder Guides webpage.

groups worldwide who are studying the different aspects of this syndrome. Of particular mention is the recent study (Blyth 2015), referred to often in this guide, which describes findings from the developmental assessment and clinical examination of twenty-two people with Pallister-Killian syndrome. Another large scale study of 59 individuals with PKS carried out in the US (Wilkens 2012) is a great source of information and is also often referred to in this guide.

Genes

The critical region of chromosome 12p that causes PKS is thought to lie somewhere between the end of the p arm and band 12.3. This region is known to contain over 300 genes. A change in expression of any of these genes can consequently cause altered expression of other genes on other chromosomes. A recent study (Kaur 2014) identified a PKS gene expression profile using fibroblast cells from patients with Pallister-Killian syndrome. The report suggests a critical region on 12p13.31 (this band contains an estimated 129 genes) and identified a change in expression of 354 genes.

Advice from parents of children with PKS

" PKS is a rollercoaster, great highs and great lows, celebrate all those tiny little achievements because for our kids a smile is massive, holding a rattle is massive. But also there seems to be a difference in how badly our children are affected, do not give up hope, trust your judgment, a lot of the time we are the experts in our child's care. "

" Laugh a lot with your child. Spoil them as much as you can. Expect nothing from them. Marvel in their achievements no matter how small. "

" It's all too easy to get weighed down with what they can't do, instead of concentrating on what they can. And just remember that there are others that you can talk to that know exactly how you feel. "

" This was our first exposure to the special needs world. We reached out to social media and found a parent support group. We ordered special needs catalogs to see what type of equipment would make our lives easier. We have always made sure to take care of each other since it can be a demanding parental role. We get respite help and ask for assistance because we know that we are better parents when we have taken care of ourselves. We also share our story with whomever will listen and hope that it gives others an appreciation and gratitude for life. We celebrate the little things, honor the quirky things about our family but it wasn't always like this. We had to evolve to get to this place. The first few years were so new and there was a lot of fear. At some point, we decided to stop living with fear running our days and to just be in the moment more. Everything became lighter then. "

" The biggest issue with PKS is that not 1 child is the same, to compare 1 child against another with this syndrome is not the right thing to do. You need to take each day and milestone as it comes and not set expectations, they'll get there when and if they can. Typical symptoms go out the window. "

The additional isochromosome usually comes from the mother but sometimes comes from the father. This type of chromosome error is more common among older parents and among Unique members many were older. Mothers' ages ranged from 20 to 42 while fathers' ages ranged from 28 to 50. The average maternal age in a recent study of 59 individuals with PKS (Wilkens 2012) was 31.7 years and paternal age 34.9 years. Other studies have also reported a link to parental age (Wenger 1988; Blyth 2015).

The error is thought to arise during the process that leads to the formation of the egg and sperm cells. During this process, a cell with 46 chromosomes (23 pairs) usually separates to make two egg or sperm cells with 23 single chromosomes in each. A fairly common error is a failure of this natural separation (non-disjunction), so that one of the new cells contains both copies of chromosome 12. The 12p isochromosome is then created when one chromosome 12 splits horizontally near the centromere instead of the usual vertical divide. The two copies of the long arm (q arm) are subsequently lost. Mosaicism then arises soon after conception when the isochromosome is lost from one or more cell lines. The alternative scenario is that the additional chromosome has arisen from a mistake in cell division after conception (Turleau 1996; Dutly 1998; Struthers 1999; Dufke 2001).

The additional chromosome usually consists of the entire short arm. However, a child with typical PKS features has been described with an isochromosome made up of the end of 12p to p12.3. This infers that their may be a critical region that causes PKS in this segment of the chromosome (Dufke 2001). Tetrasomy 12p can also occur where the duplicated p arms (or partial p arms) are integrated into an existing chromosome 12 as opposed to forming a separate isochromosome. This appears to be rarer and these children would not be expected to have a mosaic picture but Unique does have one such member whose features resemble those of a typical PKS profile.

Can it happen again?

PKS has only been known to occur sporadically, so that the affected couple and other family members (including siblings of those with mosaic tetrasomy 12p) appear to be no more likely to have another(a) child with PKS than anyone else in the population. However, there is a very small theoretical possibility that one parent's ovaries or testes contain a proportion of cells with the additional 12p isochromosome. This would increase the chances of a recurrence and is the reason you may be offered prenatal testing in your next pregnancy. Anyone with mosaic tetrasomy 12p who is thinking about having children should also have a talk first with a genetic counselling service (Doray 2002). As far as we are aware there has never been a report of a family having a second child with PKS.

Research

The name Pallister-Killian comes from the researchers who first described the syndrome (Dr Philip Pallister in 1977 and Wolfgang Killian in 1981). Since then over 200 research articles relating to PKS have been published by the many

Diagnosis

Chromosome disorders are usually diagnosed by examining DNA taken from white blood cells. However, children with mosaic tetrasomy 12p often appear to have normal chromosomes in their blood cells, so the diagnosis is usually made from skin cells or cells taken from inside the cheek (buccal mucosa). Samples may be analysed by a simple chromosome counting technique (karyotyping) or chromosomes may be analysed more closely using a technique called fluorescence *in situ* hybridization (FISH) or array comparative genomic hybridisation (CGH). The results you are given will depend upon the way your child's samples were analysed.

Results of a chromosome test

Karyotype example

Most cells in our body contain two copies of each 'autosomal' chromosome (numbered 1 to 22) and two 'sex' chromosomes, either 2 X's (female) or an X and a Y (male). When a cell sample is taken and prepared in a specific way, the chromosomes can be seen under a microscope and counted. This is called a karyotype, an example of which, for somebody with tetrasomy 12p, can be seen in the image below. Mosaic trisomy (three copies) and hexasomy (six copies (including two copies of the isochromosome)) have also been identified (Van den Veyver 1993; Choo.2002; Vogel 2009).

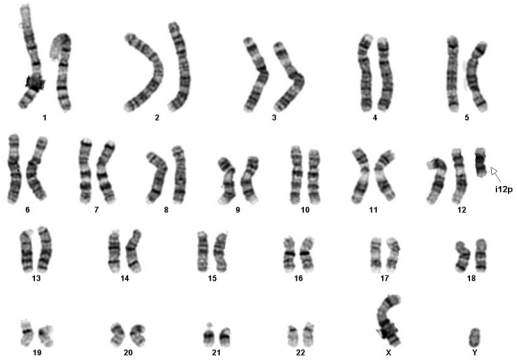

Karyotype
Tetrasomy 12p karyotpe using a basic staining technique.
The extra 12p isochromosome is indicated by an arrow and labelled i12p.

There are different ways of writing a PKS karyotype. The simplest is:
47,XY,+i(12p)/46,XY

47	The total number of chromosomes seen in some of the cells examined
XY	The two sex chromosomes. XY indicates male. XX indicates female
+i	There is an additional isochromosome
(12p)	The isochromosome is made from copies of the p arm of chromosome 12
/46	Some of the examined cells have 46 chromosomes i.e. a 'normal' chromosome count. This is because the tetrasomy is mosaic i.e. not in all cells
XY	The two sex chromosomes, X and Y. This would be XX in a female

Mosaicism and cell counts

When you are given a karyotype result, you may also be told what proportion of cells contain the extra 12p chromosome. This count does not reflect the overall proportion in the entire body. In particular it does not reflect the proportion in the vital organs, such as the brain, at critical stages of development before birth so it is not an indication as to the possible severity of the outcome (Bielanska 1996; Schaefer 1997; Doray 2002; Dong 2003; Polityko 2004; Vekemans personal communication). Severely affected children can have very low levels of abnormal cells and children so mildly affected that they do not have classical PKS can show a high ratio of abnormal cells (Schinzel 1991; Bielanska 1996; Doray 2002; Genevieve 2003). The percentage of cells containing the isochromosome depends partly on the tissue examined and the age at which the test was performed. An example of a karyotype including a cell count is given below.

47,XY,+i(12p)[7]/46,XY[6]

47	The total number of chromosomes seen in some of the cells examined
XY	The two sex chromosomes. XY indicates male. (XX indicates female)
+i	There is an additional isochromosome
(12p)	The isochromosome is made from copies of the p arm of chromosome 12
[7]	Of the 13 [7+6] cells examined, 7 were seen to contain the isochromosome
/46	Some of the examined cells have 46 chromosomes i.e. a 'normal' chromosome count. This is because the tetrasomy is mosaic i.e. not in all cells
XY	The two sex chromosomes, X and Y (male). This would be XX in a female
[6]	6 of the 13 cells examined were found to have the 'normal' number of 46 chromosomes.

You may also see the karyotype written as **47,XX,+i(12)(p10)[26]/46,XX[12]**

This result shows you that in 26 of the 38 cells examined from this female (XX), 47 chromosomes were seen, including one that was an isochromosome of chromosome 12. The extra bit of information you have been given (p10) is that this isochromosome consists of two mirror images of the short p arm of chromosome 12, starting at a point known as p10. The p10 band is included in the centromere, the point where the two arms of a chromosome meet. This means that for this child the extra chromosome consists of two almost complete short arms of chromosome 12.

Banding pattern (ideogram) of the p arm of chromosome 12. The numbering starts at the centromere (yellow band at the bottom of the image) and counts upwards towards the end of the chromosome. The point known as p10 is included in the centromere.

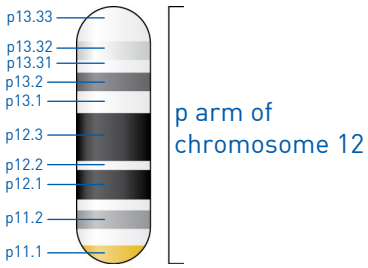

" Craig has achieved many things thought to be improbable. He walks, loves swimming, horse riding and trampolining and has a wicked sense of humour. He is a content young man who is never made to do anything he doesn't want to. I never set targets for him so he has never failed. " - Age 19

" Life has been a lot easier since Adam has grown into a young man. He helps me get him dressed and weight bears. He helps me to move him when placing him into his wheelchair. We would not be without him!. " - Age 21

" Ellie is coming up for her 26th birthday and amazes us all the time. If you read again the literature we were given when she was first diagnosed at 18 months, you would find it incredible that she lived beyond her 12th birthday! She is a very positive, funny young lady. One of the main bits of advice from me for families is to always ensure that you get plenty of support for the child but particularly for you as the carer. When they leave home you continue to be involved in their lives but it is right to make that break. We see her a lot. The girls that work with her love their jobs and enjoy every minute of being with her even with the tough times. It is a good feeling that we didn't think would ever be the case. " - Age 25

Outlook

Babies with PKS may be vulnerable shortly after birth since they are often born prematurely and can have central nervous system anomalies and apnoea (when they stop breathing). They are also prone to respiratory difficulties and may be born with a heart defect. One of the most severe problems that some babies with PKS can suffer is a diaphragmatic hernia and some do not cope with life outside the womb or the necessary surgery. However, if these possible early problems are overcome and later medical issues such as reflux, intestinal problems and seizures are dealt with, it may be possible to manage health effectively and children with PKS could expect a long lifespan. The oldest patient described in the medical literature is 45 years old.

A recent study of PKS families in the United Kingdom (Blyth 2015) identified eight individuals who had passed away. Ages ranged enormously between one hour (the baby was born at 21 weeks gestation) and 38 years. The youngest died due to prematurity, one adult died of aspiration, another of epilepsy and three children and one adult were described as having had respiratory infections at the time of death. Since Unique was set up, 79 families of children with PKS have joined, and to our knowledge seven children/adults have passed away, but we are not aware in all cases of the reasons why.

Causes

Children from all parts of the world and from all types of background have Pallister-Killian syndrome. No environmental, dietary or lifestyle factors are known to cause it. So there is nothing you did before or during pregnancy that caused PKS to occur and also there is nothing you could have done to prevent it.

Unique now has eight members over the age of 18 with PKS, a survey for five of whom was completed in 2016 (two female and three male). One male member had hypotonia until teenage years, and hearing aids from 2 to 15 years which were removed since his hearing improved. He has no speech or language and has never been able to walk unaided. His lack of eye contact, nystagmus and squint improved with age. His teeth started to come through at 2 years but he still has baby teeth in his twenties. His short hands grew to normal size as an adult. He can recognise people he is familiar with and gives them a hug. On the whole he is a happy and placid young man who enjoys any sort of sensory activity and company. His general health is excellent and he has become more aware of his environment and surroundings as he has got older. Another male member has a mild intellectual disability and his ability to learn is constantly progressing. He is able to walk and talk and does most things autonomously. He has help with social relations and is very competent with the latest technologies. The third male member over the age of 18 started to walk at age 11 years and hardly ever uses a wheel chair now. He started having seizures at 16 years and he is not able to speak but he does not have any visual or hearing impairments. He loves water, trampolining, walking, eating, music, horse riding and skating.

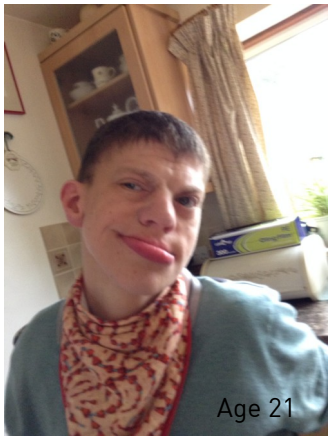

One female member walked confidently from the age of 7 but became weaker due to epilepsy and medication. She is however starting to regain her skills. She is in supported living with waking night staff and a monitor since she has sleep apnoea and unpredictable seizures. Although she has osteoporosis she is 'amazingly healthy' on the whole and recovers quickly from illness. She loves music and really enjoys travelling on buses, trains and aeroplanes. She left school at 19 and went to residential college for 4 years. She now has a very active weekly timetable. Parents of another member mentioned how their daughter has become more mature and relaxed now she is an adult. She enjoys listening to music and going on outings. She attends a special care centre and is also in excellent health. She had seizures in the first few months of life but does not have them now, she is able to talk in short sentences.

FISH example

Cells can also be analysed by a technique called FISH (fluorescence *in situ* hybridisation). This technique uses fluorescently labelled pieces of DNA that match the DNA in specific places on a chromosome so this test will only be offered if tetrasomy 12p is suspected. An example of a FISH result is shown below.

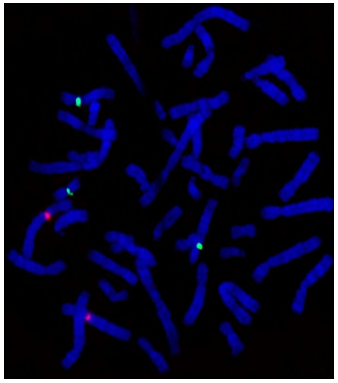

This is an example of a FISH test result showing a chromosome 12p isochromosome. All chromosomes are stained blue and the DNA at the centromere (the point where two chromosome arms meet) of the two chromosome 12's is labelled green. The centromere of the 12p isochromosome is also labelled green, this is why you can see three green dots. The centromere of chromosome 6 is labelled red as a control to check the procedure worked correctly.

Array CGH example

A recent test now available to detect differences in the DNA content of chromosomes is called microarray comparative genomic hybridisation (array CGH). This technique allows DNA to be analysed in great detail and can detect duplications even when this diagnosis is not suspected. An example of an array CGH analysis is given below.

arr[hg19] 12pterp11.1 (1-34647404)gain

arr The analysis used microarray technology

[hg19] Human Genome build 19. This is the reference DNA sequence that the base pair numbers refer to. As more information about the human genome is found, new 'builds' of the genome are made and the base pair numbers may be adjusted

12p DNA from chromosome 12 is duplicated

pterp11.11 The duplicated DNA is from pter (the terminal end of the p arm to p11.1 (which is at the other end of the p arm close to the centromere).

(1-34647404) The duplicated fragment is identified by its base pair position (the exact points where the chromosome has been duplicated). In this case, the extra piece of DNA is from 1 bp to 34647404 bp

gain There is more of this section of DNA than expected. Further testing is required to determine whether there is an isochromosome, or whether the additional DNA is joined onto one of the 'normal' 46 chromosomes.

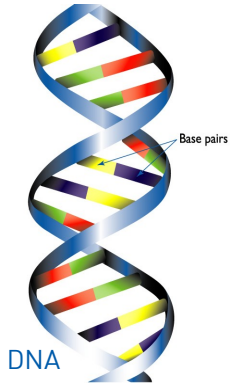

Cell samples and diagnosis

During pregnancy, mosaic tetrasomy 12p can sometimes be confirmed from a sample of chorionic villus (CVS) tissue taken from the developing placenta around 10 weeks after fertilisation. CVS cells develop from the same fertilised egg as the embryo (developing baby) and usually share the same DNA (chromosomes). However, the CVS cells do not always reflect those in the baby and this test may miss the diagnosis. If the baby's features suggest PKS but the CVS result comes back negative, an amniocentesis is needed. Chromosome diagnosis on cells obtained by amniocentesis is usually accurate, especially if FISH using a chromosome 12 specific probe is used to increase certainty (see page 4).

After a baby's birth, chromosomes from a blood sample are usually examined first, but in PKS this often produces a normal result. This is because in cell types that have a rapid turnover, such as white blood cells or bone marrow, the cell line with the extra chromosome tends to be lost in favour of the cell line with normal chromosomes. A blood sample taken within days of birth may, however, still reveal some cells with the extra chromosome. Tissues with a slower cell turnover such as skin or the mucous covering of the inside of the mouth (a buccal smear) are more likely to reveal the additional chromosome for longer (Manasse 2000).

Late diagnosis of PKS is common due to false negative test results, usually from blood samples. Dr Moira Blyth, who took part in Unique's PKS study weekend, carried out an in depth study of UK families who have a child with PKS (Blyth 2015). Twenty-two children known to have PKS were assessed, the majority of whom were given repeat DNA tests. Of the 20 children who had their chromosomes investigated by FISH analysis of cheek cells, 15 tested positive for PKS (75%). Of the 19 children tested by array CGH using DNA from a blood sample, three tested positive for PKS (15.8%). During this study, two children were identified as having previously unidentified hexasomy 12p (six copies of 12p), one of whom was mosaic hexasomy/tetrasomy meaning that some cells were identified as having six copies of 12p, and some cells had four copies.

Age at Diagnosis

Since the outcome of having mosaic tetrasomy 12p is so variable, babies and children are diagnosed at various stages of development. Those who are born with obvious physical problems such as a diaphragmatic hernia are more likely to be tested at birth, or during pregnancy if this is identified during routine screening. Others may be offered a genetic test if other unusual features are observed at birth. The majority of Unique members were identified as babies or toddlers due to concerns such as developmental delay, floppiness, feeding problems or lack of eye contact. However, some Unique members were diagnosed later in childhood (the oldest being almost 6 years) since a genetic test was not offered or a false negative result was initially received.

Puberty

There is very limited information available on puberty in children with PKS. The information that exists suggests that in some children it may proceed normally or be slightly delayed and full secondary sexual characteristics (such as body hair) may not develop fully. Girls who find periods difficult to cope with may be given long-term contraceptive injections or implants to control them.

When this guide was revised in 2016, Unique had 24 family members with a child aged between 13 and 19 years, 5 of whom completed a survey (3 boys and 2 girls). One girl was described as grumpy and sleepy during puberty and accessory nipples under her arms developed slightly. The second girl went through puberty at a standard age and showed signs of increased anxiety and aggression which later calmed. A third girl, who is now an adult, had an increase in frequency and strength of seizures during puberty as well as a lengthy menstrual cycle. One parent of a teenage boy mentioned that her son has all the features of puberty, physical and behavioural. Another parent mentioned that her son, like any teenager, would be happy to stay in his bed.

Adults

Many children with PKS remain dependent on their carers for all aspects of personal care, but this is not true of all. Those who are less severely affected may become toilet trained during the day time before school age and at night before they reach secondary school age. They learn to brush their teeth (an electric toothbrush helps) and hair, to dress and to wash themselves. However, only those children who are so mildly affected by tetrasomy 12p mosaicism that they do not have classic PKS achieve a level of life skills that will allow them to live independently. Among adults, the level of physical disability differs considerably, as do language and communication skills.

Behaviour

Most babies and children with PKS known to Unique are placid and tend not to take the initiative or interact spontaneously with their environment. Although some children are sociable, others prefer to be left alone and some dislike being touched. In general, they behave like children younger than themselves. Any behaviour problems tend to arise in older children and appear to be more common in those with more extensive communication and cognitive disabilities. A few Unique members have reported their child holds their breath for a worryingly long time or attempts to poke their finger behind their eyeball, these may be sensory actions. Episodic hyperventilation (periods of breathing too deeply or rapidly) has also been reported (Blyth 2015).

A recent study looked at the behavioural characteristics of a group of 16 girls and 10 boys with PKS with an age range of 18 months to 19 years (Kostanecka 2012). Of the 26 participants, 14 were not able to walk or talk. Irritability (including self-injurious behaviour), lethargy, stereotypy (repetitive movements), hyperactivity, and inappropriate speech were assessed. Repetitive hand and body movements were noticed in 12 participants; self-injurious behaviour, such as hand or finger biting and head banging were reported in four individuals; 11 children were reported as 'lethargic and withdrawn'; five children were described as 'drowsy during daily activities'; eight were described as having hyperactivity (seven of whom were also described as having lethargy). The majority had profound intellectual disability. In Unique's experience, although a few parents mentioned that their child does not like to be touched, most commented on how happy, placid and friendly their child is.

" N does not like to be handled, likes to lie down and roll from side to side, and is very defensive when being touched. " - Age 6

" Simon is a very laid back boy. If he cries, I KNOW something is wrong, it's so rare. He's smiley, laughs often and is very content. " - Age 12

" Extremely placid and loving, lots of smiles and generally happy. " - Age 12

Age 13 with younger sister

How common is PKS?

It is difficult to estimate the prevalence of PKS since many children will not have been diagnosed, and many of those who are diagnosed are not reported in the literature. However recent studies have reported a birth incidence of 5.1 per million live births (Blyth 2015). Fifteen years ago, just over 100 people with PKS had been described in the medical literature (Dufke 2001). Today (2016), the count has increased to over 200. Unique currently has 71 members with PKS who live worldwide.

Main features

Features of PKS vary considerably but the main features are as follows:

- Floppiness (hypotonia)
- Mild to profound intellectual disability
- Speech delay or absence
- Developmental delay
- Seizures
- Specific facial features

Specific facial features may include one or more of the following: high arched or cleft palate (roof of the mouth); prominent forehead; broad nasal bridge; widely spaced eyes (hypertelorism/telecanthus); skin folds across the inner corner of the eye (epicanthic folds); forward facing nostrils (anteverted nares); large mouth with thin upper lip and/or thick lower lip; large tongue; long philtrum (the groove between the nose and the upper lip) that may extend into the lip; low-set, backwards-rotated ears; sparse eyebrows/eyelashes; areas of alopecia (sparse hair or bald patches around the temples) that improve with age; small lower jaw (micrognathia) in children and large lower jaw (prognathia) in adults; short neck.

Other features

- Heart condition
- Anal atresia (the anus may be closed or absent)
- Sacral appendage (bony outgrowth at the base of the spine)
- Short arms, legs, hands, feet, fingers or toes
- Diaphragmatic hernia (a hole in the muscular wall separating the heart and lungs from the contents of the abdomen)
- Exomphalos (a defect in the abdominal wall that causes the intestines, liver and occasionally other organs to remain outside of the abdomen in a sac)
- Polydactyly (extra fingers or toes)
- Hypopigmented and/or hyperpigmented lesions (patches of lighter or darker skin)
- Supernumerary nipples (extra nipples)
- Anhydrosis or hypohydrosis (deficiency or absence of sweating)

These features, and others found to be associated with PKS are explained in more detail later in this guide.

Pregnancy

While pregnancies with mosaic tetrasomy 12p are often unremarkable, polyhydramnios (unusually large amount of amniotic fluid) has been seen both in pregnancies where babies have physical anomalies and where they have none. Too much amniotic fluid can lead to premature delivery. Fifteen Unique members mentioned their child with mosaic tetrasomy 12p was born early (between 1 and 13 weeks earlier than expected) and 14 mothers reported polyhydramnios. Typical anomalies observed on ultrasound scans are increased nuchal translucency (the thickness of the fold at the back of the neck), short arms and legs, a diaphragmatic hernia, and heart defects. Some doctors have suggested that some of the typical facial features (small nose, thin lips) can also be detected by mid-pregnancy ultrasound (Mathieu 1997; Schaefer 1997; Langford 2000; Paladini 2000). Some babies with tetrasomy 12p were also identified as having ventriculomegaly (enlargement of the fluid-filled spaces in the brain) during routine pregnancy scans. A genetic test during pregnancy is advised if there are concerns about fetal development or an anomaly is detected.

Birth

Many babies are born early and are large for dates. Among the 25 Unique babies whose birth weight is known, the heaviest baby weighed 4650 grams (10lb 4oz), while the lightest weighed 1276 grams (2lb 1oz) and was born at 29 weeks. Occasionally, babies have been found with hydrops. This is a severe bloating of tissues caused by excess fluid due to the baby's inability to manage fluid and it can overwhelm the baby's organs (Schinzel 1991; Langford 2000; Paladini 2000; Dorey 2002). Low Apgar scores are common and babies can be profoundly hypotonic (floppy) at birth, experience distress, need resuscitation and in some cases care in the neonatal intensive care unit. Breathing is commonly affected, so additional oxygen is required and some babies need to spend at least a short time on a ventilator. A genetic test is commonly carried out after birth if the baby has any unusual symptoms as described earlier in this guide. Some babies have large fontanelles ('soft spots' on the skull) which may close later than usual.

astigmatism (a defect that results in a distorted image) and disordered depth perception, making it hard to identify steps and other changes of level. Other children have cortical visual impairment (a condition in which the visual systems in the brain do not understand or interpret what the eyes see) and defects in the ability to focus the eyes properly are common. Many children have rapid involuntary eye movements (nystagmus) and some also have a squint (strabismus) (Mathieu 1997; Unique). A recent study reported 17 out of 22 people with PKS as having a visual impairment (Blyth 2015) and an earlier study reported 39 out of 45 people with PKS had some form of ophthalmological involvement (Wilkins 2012). Other optic conditions reported in children with PKS include atrophy (wasting away) or hypoplasia (underdevelopment) of the optic nerve and ptosis (drooping upper eyelid). Of the 49 members who have given Unique information about their child's eyes, 27 mentioned some form of visual impairment, 20 children were noted as having nystagmus, 10 have a strabismus, 5 have an astigmatism, 4 have an optic nerve anomaly and 6 have ptosis. One family reported that their child has a dissociated vertical deviation, where one eye drifts upwards, one child has low pigmentation of the iris, one family mentioned their child's pupil's do not dilate and three members have very small pupils. One Unique member has macula degeneration, one has bilateral cataracts and one has hypopigmented patches on their retina.

Skin pigmentation

Streaks or patches of lighter or darker skin are highly typical of mosaic tetrasomy 12p. The under- or overpigmented skin can occur anywhere on the body, or less commonly on the face. In children with mosaic tetrasomy 12p without typical PKS, it may be the only visible sign. The altered skin colour is not always visible at birth and in some children only becomes obvious after sun exposure. Children with PKS may also have lax or redundant skin.

Age 8

Lymphoedema

Occasionally children or adults with PKS develop lymphoedema, a condition that causes swelling of the body's tissues, usually in the arms or legs.

Ears and Hearing

You may notice even before diagnosis that your baby does not respond to sound. Just over a third of children with PKS are thought to have a hearing impairment. A recent study reported that 36 out of 47 people with PKS in the US had some form of auditory problem, either sensorineural (permanent defect of the inner ear or neural connections), conductive (problem conducting sound waves anywhere along the route through the outer and middle ear), mixed or unspecified (Wilkins 2012). In a UK study (Blyth 2015), 17 out of 22 people with PKS were reported to have a hearing impairment. The precise cause of the hearing loss is not yet understood. In younger children the severity can be difficult to assess but in children whose hearing has been measured it ranges considerably from mild to profound and can affect one or both ears. Children with high or cleft palates are vulnerable to conductive hearing loss caused by glue ear and some children with PKS will be helped by grommets or longer term T-tubes to improve the function of the ear drum (Horneff 1993; Schuster 2002). Six Unique members mentioned their child had had either temporary or permanent tubes fitted, 5 parents mentioned their child had glue ear, 7 children are known to have had ear infections and two were noted to have narrow ear canals. Those with sensorineural or significant conductive hearing loss may require hearing aids. Fourteen Unique members are known to use hearing aids. However, a few Unique parents have said that their child's hearing has improved with age (this is common with conductive hearing impairment) and in two cases hearing aids were removed when the child's hearing improved (age 6 and 15 years). Twenty four Unique members have not given Unique information regarding their child's ears and three children are known to be under investigation but 7 parents stated their child had no hearing impairment. Some children with PKS also have posterior ear pits which are small 'dents 'in the skin behind the ear (Wilkens 2012).

Eyes and Vision

You may also notice that your baby/child has a problem with their eyes, as this is commonly associated with PKS. In some the effect is minor, including

Babies

If a baby is not diagnosed during pregnancy or at birth, delays in reaching developmental milestones or lack of eye contact are a common early indication. Failing standard developmental assessments may also prompt a genetic test. However, as mentioned earlier, late diagnosis of PKS is common due to false negative blood test results.

Feeding

Many PKS babies have successfully breastfed for months although some needed a period of bottle feeding or spoon feeding and a few have needed a nasogastric tube (a tube leading to the stomach that is inserted via the nose to allow all feeds and medicines to be taken directly) or gastrostomy (a feeding button). Babies with a cleft or very high arched palate (described in just over a third of the Unique series) have faced particular difficulties and in Unique's experience they have fed more successfully from a feeder designed especially for babies with sucking difficulties. The underlying low muscle tone makes feeding a particular effort for most PKS babies and while some feed adequately, they may still lose weight and need supplementation with a high energy formula.

A minority of babies have reflux, where feeds readily return up the food pipe from the stomach. In most cases this has been controlled with medication and feed thickeners as well as careful positioning. If these steps do not control reflux, it is possible to tighten the valve between the stomach and the food pipe with a surgical operation known as a fundoplication.

Some PKS babies are reluctant to feed since their sucking reflex is not developed or they find it difficult to co-ordinate sucking, swallowing and breathing. These difficulties may be exacerbated by palate anomalies. Occasionally babies have a cleft in the uvula (the extension of the soft palate that hangs from the roof of the mouth above the back of the tongue). Once babies move on to solids, they typically need mashed or puréed food for longer than other children. While some children remain unable to chew and continue to need their food finely chopped, others progress to family foods by mid childhood.

Sleep Sleep disorders are not a specific feature of PKS and many families describe sleep disruption that is no different to any other young child. However, a few Unique families have reported a continuation of the newborn sleeping pattern with their child unable to distinguish day from night and many families record that their babies sleep for very long hours until a much greater age than other children. Once children learn to sit up and relate to their surroundings the great need for sleep appears to abate. In the meantime, very short therapy sessions may need to be scheduled in order to sustain a child's wakefulness.

Children

Once your child has shown their individual pattern of development it will become easier to predict their longer term possibilities. Older medical texts from the early 1990s tend to paint a gloomy picture. While it is true that some children will be very delayed in walking and some may not walk, others may only have mild learning difficulties or none at all. However, mildly affected children are thought to be rare (Schinzel 1991; Doray 2002). The mosaic nature of PKS makes predicting a child's outlook very difficult. This is particularly true for babies diagnosed before birth, where the additional chromosome has been identified without any clear indication as to severity. Ultrasound scans can reveal physical problems but cannot tell you about a child's future cognitive ability, their character or how high a quality of life they will have.

Mobility

The hypotonia that affects babies from birth tends to persist at least into early childhood, and babies with PKS are delayed in reaching their motor development milestones. The range of delay is very varied, with the age at which children in the Unique series first sit up or roll over and become mobile ranging from 3 months to 8 years 7 months. The age at which children take their first steps varies between 1 year 7 months and 9 years and some children need supportive footwear, splints, standers and walking aids to achieve this. Although babies are late to roll and sit up, some learn to scoot on their backs. In general, babies who

Spine and Bones

The full examination of a baby/child with PKS will include the spine and, in some cases, imaging may be required. While most children in the Unique series have no spinal abnormalities, a small number of children have a degree of spina bifida, due to incomplete development during fetal life of the spinal column. None of the Unique series has an open spina bifida, but one child has the occult form and another has a tethered spinal cord, in which the cord is abnormally stretched and surgery is recommended to prevent neurological deterioration. While in spina bifida occulta the spinal cord is usually intact, in some children there is a loss of sensation affecting the lower limbs and bowel and bladder control. The presence of a sacral appendage (a small outgrowth at the base of the spine) has been reported but is not common.

Some babies develop a spinal curvature during childhood (scoliosis or kyphosis) and require adapted seating, bracing and sometimes surgery to straighten the back. Eleven Unique members are known to have scoliosis/kyphosis and for some, this was only apparent during the teenage years following a growth spurt. Recent studies have found that some children with PKS show a mild pattern of skeletal changes including delayed ossification (when cartilage is transformed into bone). They may also have flared anterior ribs, and broad metaphyses of the long bones (wide portion of the bone, near the end, that grows during childhood; Jamuar 2012). They may also have fewer ribs than expected. Some children have congenital hip dysplasia (abnormal development of the hip joints that is present at birth) or hip dislocation later in life that may be related to late weight bearing.

Age 13

Hands and feet

The typical PKS features affecting the hands and feet are an extra finger or toe, although this is not very common. Parents more commonly observe short hands and/or feet. Fingers and/or toes may also be short and/or curved (clinodactyly). Some children have a degree of deformity of the angle of the feet, including club foot and flat feet (Schinzel 1991; Horneff 1993). Some children also have a single crease on the palm of their hands.

paediatric neurologist at Great Ormond Street Hospital, discusses the different types of seizures and medication. Other forms of seizure control such as a medically supervised ketogenic diet are also discussed. Such a diet has proved successful for some children with PKS who have drug-resistant epilepsy.

Brain

Brain imaging investigations may be performed in babies and children diagnosed with PKS. The two cerebral conditions reported most frequently in the Unique series are atrophy (where the brain is smaller than expected) and hydrocephalus (an excess of cerebrospinal fluid in the brain). A recent study identified structural brain abnormalities in 24 of 33 patients with PKS (Wilkens 2012) but only 12 Unique members have reported brain anomalies in their child.

Heart

Over a quarter of babies with PKS are thought to be born with a heart condition (Wilkens 2012; Tilton 2013; Blyth 2015), most commonly a ventricular septal defect (a hole in the wall between the two pumping chambers of the heart) or an atrial septal defect (a hole in the muscular wall between the two filling parts of the heart). All babies/children diagnosed with PKS will have a thorough cardiac investigation. Treatment depends partly on the size of the defect and some holes will close naturally in time. Persistent ductus arteriosus also occurs (the channel between the aorta and the pulmonary artery that takes blood to the lungs and usually closes shortly after birth remains open instead). The aorta itself may be narrowed, as may the valve that leads from the heart to the aorta. It is usually possible to expand the narrowing surgically (Schinzel 1991). If you are concerned about the health of your child's heart later in life you may wish to request a follow up check to monitor for the development of cardiomyopathy (heart muscle disease) or dilation of the aorta (main artery).

A recent study assessed the pattern of cardiac health of 81 people with PKS who had had at least one cardiac evaluation (Tilton 2013). The findings demonstrated a structural heart difference in 30 of those studied (37%), none of whom had required surgical intervention. It was noted that those with more serious heart problems may choose to not take part in studies. Seven Unique members reported that their child had a heart anomaly, all problems resolved naturally.

sit early tend to walk early and go on to become more fully mobile than babies who do not sit until four or five years. However, even late sitters and walkers and those who never walk can take part in a broad variety of activities. In 1997 it was estimated that 30 per cent of children and adults with PKS are able to walk (Mathieu 1997). A more recent study of 22 UK people with PKS (Blyth 2015) reported this value as almost 38%, while a study in the US reported 17% (Wilkins 2012).

In many children the early hypotonia improves with increased mobility and as it does so, it may be replaced by increased muscle tone. Some older children may also develop joint contractures (shortening and hardening of muscles/tendons/other tissues that can lead to rigidity of joints) or show limited extension of their elbows, and others may develop the spinal curvature of scoliosis or kyphosis (Horneff, 1993). Children may receive routine occupational and physical therapy but there are other therapies that can be of great benefit such as aquatherapy and hippotherapy (riding for the disabled).

" At 7, Federico is too hypotonic to stand alone or to walk – but he does ride with his pony instructor. "

" Physically, Phil was an early developer, sitting at 7 months, crawling at 12 months and walking alone at 22 months. At almost 8 years, he runs, swims, cycles and plays football. "

Ability to learn

Most children with PKS experience learning difficulties and for many the disability may be marked and exacerbated by hearing and vision problems. However, some children have only a mild learning difficulty. Most children attend special schools but some are in mainstream schooling with a dedicated support worker or teacher.

“ Phil started to read this year. Today he reads school books and children’s books and writes short to medium length sentences. He has a good memory and his strengths are visual memory and logic. He attends a mainstream school with a support teacher. His learning difficulties are described as moderate. ” - Age 7

“ Lauren has profound learning difficulties but she has a good memory and at the age of 7 remembers songs sung to her as a baby. She is always improving, but very slowly. ” - Age 7

Communication

Speech tends to be late to develop and may remain limited or not develop at all. A recent study (Blyth 2015) found that almost three quarters of children over the age of 18 months and adults with PKS were not talking. Many families report a lack of eye contact and communication in the early years and a tendency for their child to live in a separate world of their own. However, in the pre-school years most children communicate their likes and dislikes with vocal noises and gestures and may understand simple requests and statements. Older children benefit from tactile signing and assisted communication devices. The link between the ability to speak and to learn appears to be strong as among the older children the three most versatile learners also speak most fluently.

“ Daisy started to interact with other children outside of her siblings at 20 months. She cannot talk but does communicate through babble, grunting, shouting and some gestures. ”

“ When he was old enough to understand, I taught him makaton signing, which really helped. I also made photo cards of family members, and his favourite things, so he could show us even if he couldn’t tell us. ”

“ Emilie is non verbal. She is a very sociable and happy child. She communicates with what we recognize as happy or unhappy noises. Needs a lot of practice from the carer to decipher as can be unintentional. ”

Medical concerns

Apnoea

In Unique’s experience, many newborn babies experience apnoea (when they temporarily stop breathing) and some need long term assistance with their breathing. Some babies come home from hospital on oxygen and apnoea monitors and many parents use monitors overnight. The underlying hypotonia affects the windpipe, making it softer and more liable to collapse. A small number of babies need a tracheostomy (a tube is inserted into the windpipe to allow air and oxygen to reach the lungs). As babies mature, their muscle tone improves and they can be weaned off respiratory support.

Hernias

Diaphragmatic hernias have been associated with PKS where part of the bowel, stomach and/or liver take up space in the chest due to a hole in the muscular wall. As a consequence, the baby’s lungs and to some extent their heart, are displaced and may not have enough room to develop properly. All babies in whom this defect can be repaired need early surgery. Two Unique members have informed us that their child had a diaphragmatic hernia. Four members remarked that their child had had an inguinal hernia (a protrusion of the abdominal-cavity contents through the inguinal canal) and 3 members noted their child had had an umbilical hernia (a protrusion through the abdominal wall at the site of the navel). Four further Unique members mentioned their child had had an unspecified hernia.

Genitals/Anus/Kidneys

Slight abnormalities of the genitals are fairly common although they rarely need surgical repair. In girls the anus and vagina may be unusually close together (anteriorly placed anus), while in boys the genitals may be small and the testes may not have descended into the scrotum. An operation to bring down the testes and anchor them may be recommended. An occasional finding in girls is a closed vagina. A closed (imperforate) anus has also been reported. Structural anomalies of the kidney have been reported as has decreased renal function but only in a few children (Wilkens 2012).

Seizures

Seizures affect about half of the children with PKS known to Unique and those described in the medical literature, although this value varies greatly between reports and may be dependent on the selection method for each study and the age of the participants (Candee 2012; Giordano 2012; Kostanecka 2012; Wilkens 2012; Blyth 2015). Seizures may start in babyhood, in childhood or not until puberty or adulthood. Seizures types vary, with nocturnal seizures reported by some families. Families do not perceive a link between seizure activity and their child’s ability to learn. Some children with reasonably fluent speech also have seizures. More detailed information about seizures relating to PKS can be found in the Unique study weekend report where Dr Christin Eltze, consultant