



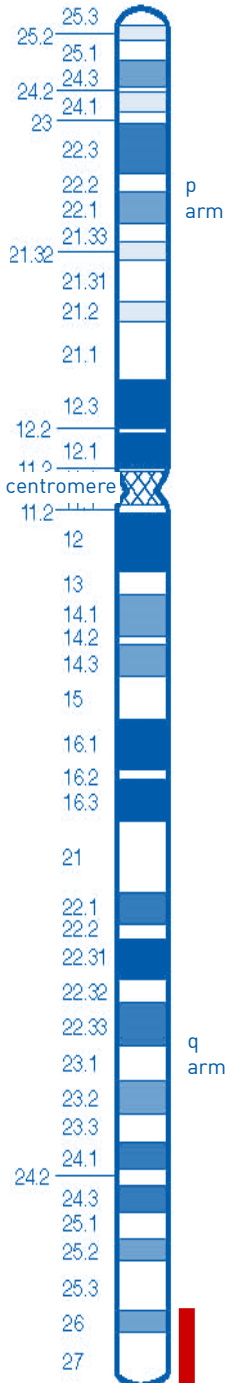
Understanding Chromosome & Gene Disorders

6q deletions from 6q26 and 6q27



rarechromo.org

Chromosome 6



A chromosome 6q deletion means that part of one of the body's chromosomes, chromosome 6, has been lost or deleted. If the missing part contains important instructions for the body, some learning difficulties or disability, developmental delay and health problems may occur. How serious these problems are depends on how much of the chromosome has been deleted and where the deletion is.

Genes and chromosomes

Our bodies are made up of billions of cells. Most cells contain a complete set of genes. We have thousands of genes which act like a set of instructions, controlling our growth, development and how our bodies work.

Genes are carried on microscopically small, thread-like structures called chromosomes. We usually have 46 chromosomes, 23 inherited from our mother and 23 inherited from our father, so we have two sets of 23 chromosomes in 'pairs'. Chromosomes and genes are made up of a chemical substance called DNA.

Apart from two sex chromosomes (two Xs for a girl and an X and a Y for a boy), chromosomes are numbered 1 to 22, generally from largest to smallest. Each chromosome has a short (p) arm (at the top in the diagram) and a long (q) arm (at the bottom). In a 6q deletion, material has been lost from the long arm of one chromosome 6.

The chromosome may have broken in two places and the part between them is missing (an **interstitial** deletion) or it may have broken in one place and the part of the chromosome from the breakpoint to the end of the arm is missing (a **terminal** deletion). The ends of chromosomes are called telomeres and a deletion from close to the end is sometimes called a **subtelomeric** deletion.

Looking at 6q26 and 6q27

You cannot see chromosomes with the naked eye, but if you stain them and magnify their image under a microscope, you can see that each one has a distinctive pattern of light and dark bands. Bands 6q26 and 6q27 are the last bands before the tip of the long arm of chromosome 6. This guide tells you about the effects of losing DNA from these bands.

The missing piece of chromosome can be tiny or much

larger. Conventional chromosome analysis uses magnification under a microscope to find changes in chromosomes. If the missing piece is large enough to be visible under a microscope, it is called a deletion. Sometimes the missing piece is so tiny that it can only be identified using molecular or DNA technology, in particular a technique using microarrays (array-CGH), that shows losses and gains (called duplications) of tiny amounts of DNA throughout the genome. A tiny loss is called a **microdeletion**. Smaller deletions generally remove fewer genes and newer molecular techniques can usually show whether particular genes or parts of genes are present or not.

People with a deletion from 6q26 or 6q27 have different sizes of deletion. The size of small deletions and microdeletions is often measured in pairs of bases, called **base pairs**. These are the pairs of chemicals [bases] that are linked by the 'rungs' in the ladder-like structure of DNA. Since each chromosome has millions of base pairs the numbers in the base pair coordinates are very long. Often they are shortened, like this: one thousand base pairs can be shortened to 1 kb; one million base pairs can be shortened to 1Mb. The amount of material lost from 6q26-7 can be anything from 500kb [or even less] to 13Mb.

Genetic testing

Techniques that are commonly used include FISH and microarrays:

- **Fluorescence *in situ* hybridisation (FISH) uses fluorescent dyes to visualise under a microscope the number of copies of small sections of chromosomes. Unique publishes a separate guide to FISH**

However, rare chromosome disorders may be caused by subtle changes in the chromosomes that are too small to see using a microscope.

- **Microarray comparative genomic hybridisation (array CGH) is a sensitive technique which shows gains (and losses) of tiny amounts of DNA throughout the chromosomes. Array CGH identifies duplicated, disrupted or absent DNA. Unique publishes a separate guide to array CGH.**

Array CGH report

The laboratory that finds the 6q deletion will send a report that may look like something like this:

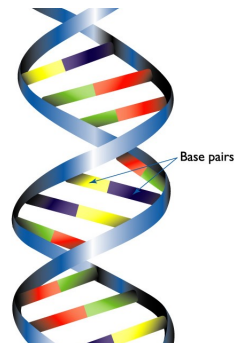
46,X,Y,arr[hg19] del[6](q26q27)[164178309-171115067]x1 dn

46 The total number of chromosomes in your child's cells

XY The two sex chromosomes: XY shows a male; XX shows a female

arr The analysis used microarray technology

hg 19 This refers to the version of the human genome [all the chromosomes] used. Currently the latest version is hg19. In older versions the base pair coordinates may be different.



1 base pair = bp
 1,000 base pairs = 1kb
 1,000,000 base pairs = 1Mb

- del** Material has been lost [deleted]
- (6)** The material has been lost from one of the two chromosome 6s
- (q26q27)** There are two breaks in the chromosome: one in band q26, the second in band q27. The material between the two breaks is missing
- (164178309-171115067)**
The base pairs between 164178309 (around 164 Mb) and 171115067 (around 171 Mb) have been shown to be missing. Take the first long number from the second and you get 6,936,758. This is the number of missing base pairs.
- x1** means there is just one copy of these base pairs, not two – one on each chromosome 6 – as you would expect.
- dn** The deletion occurred as a 'new event'. The parents' chromosomes have been checked and no deletion or other relevant change found at 6q26-7. The deletion is then very unlikely to be inherited so any possibility of the parents having another child with the deletion is very small.

Instead of a chromosomal microarray, you have a molecular analysis such as a FISH test. This is an example of FISH analysis:

46,XY.ish del(6)(q27q27)(wcp6+, VIJyRM2158-)

Here, the letters **.ish** tell you that the analysis was by FISH. **wcp6+** tells you that a technique known as whole chromosome painting identified the chromosome being investigated as number 6. **VIJyRM2158** is a region of DNA within the 6q27 band. The minus (-) sign means that this region was missing.

Recent studies using molecular techniques have shown that individuals with 6q26 and 6q27 deletions have many different breakpoints and there is probably no single 'hot spot' for breakages in these bands. What is more, there is no obvious relationship between the size of the deletion and how obviously an individual is affected. Some people with very small deletions are severely affected while others with apparently larger amounts of missing material are more mildly affected.

But some features and health problems are similar in people with a 6q26 and 6q27 deletion. This guide describes the things that are similar.

Sources & references

The information in this guide is drawn partly from medical publications. The first-named author and publication date are given to allow you to look for articles on the internet in PubMed. The leaflet also draws on Unique's database. When this guide was written, Unique had 67 members with a 6q deletion, of whom 46 had a pure 6q deletion with no other chromosome involved.

In this guide, some 49 cases with a pure deletion of 6q26 or 6q27 are described, 22 from the medical literature and 27 members of Unique. The oldest member of Unique was 20 years old when this information guide was revised and the oldest person described in the medical literature was a grandmother. There are additional very brief patient reports in reviews of subtelomere screening in the medical literature (Rossi 2001; Adeyinka 2005; Le Caignec 2005; Ravnán 2005; Sherr 2005) but these are not included here. (Rigon 2011; Mosca 2010; Bertini 2006; Elia 2006; Rooms 2006; Striano 2006; Eash 2005; Stevenson 2004; Kraus 2003; Anderlid 2002; Lorda-Sanchez 2000; McLeod 1990; Unique).

At birth

Range of birthweights at or near term: 5lb 13oz/2.6 kg to 10lb 5oz/4.68kg. Most babies' length and weight were in proportion but some babies, although not all, had a relatively small head. Babies' condition at birth was reasonably good, with Apgar scores (rating of the baby's wellbeing on a scale of 0-10) ranging from 7 to 10 at one and five minutes after birth.

What was unusual?	How many babies were affected?
■ Feeding difficulties	Frequent, especially among Unique members
■ Sacral dimple/ spinal lipoma	11/50
■ Usually, normal growth with lean build	Most
■ Usually, healthy	Most
■ Low muscle tone	Common

First signs

In many newborn babies there was no sign of anything unexpected. A minority of babies were hypotonic (low muscle tone, they felt floppy to hold), lethargic and had early feeding difficulties. In most, however, delayed development was the first sign of the chromosome disorder and in one child the first signs emerged only by the age of four. In some families with a 6q27 deletion, relatives with the deletion - both adults and children - were only diagnosed during family testing. A relatively small head was the first sign in some babies; one also had clenched hands, with unbent fifth fingers. Other babies had a dimple at the base of the spine and one had a tiny hole in the cheeks in front of the ears and webbed toes as well. In others, the first sign was seizures.

Feeding

Many babies with a chromosome disorder do have initial feeding difficulties and the evidence from Unique is that they are quite common among babies with a 6q26 or 6q27 deletion. But some babies do breastfeed without any difficulties and progress to solid foods at the appropriate age. Others have feeding problems, but the range of severity is very broad, from babies with low muscle tone at birth who need temporary help by feeding with a nasogastric tube to one child who was still fed by tube direct into the stomach and could take no food by mouth at the age of four. Some families mention that their child has a small appetite and a few young children have been diagnosed with failure to thrive, weight gain significantly below other babies of a similar age and sex. Others note difficulty with solids, chewing and eating a narrow range of foods. In some

babies and young children a high palate contributes to the feeding difficulties. One child was eating excessively by adolescence.

“ He was breastfed to two years after some minor difficulties with latching on. Once on solids, food would get stuck in his mouth and he had most of his food mashed until he was three and a half. Until the age of eight, we had to be cautious about food ” - *6q27qter deletion, 14 years*

Gastro oesophageal reflux (GORD, GERD), where the stomach contents return up the food passage, affected at least five Unique members. Reflux raises a baby’s risk of inhaling food contents and setting up an infection in the lungs known as aspiration pneumonia. Reflux can be eased by careful semi-upright positioning during and after feeds, sleeping in a prescribed sleep chair rather than a bed, raising the head end of the baby’s cot and if necessary by prescribed medication that helps to keep the feed within the stomach and counteract any acidity. Babies who have continuing problems can have a surgical procedure called a fundoplication to improve the action of the valve at the junction of the food pipe and stomach. Where feeding and reflux problems are persistent, a gastrostomy tube (PEG, button) can be inserted to allow direct feeding into the stomach until the baby is sufficiently mature to tolerate feeding by mouth. In the experience of Unique’s members, reflux settled after the first or second year of life, except for one child who needed a fundoplication and whose reflux significantly disrupted sleep.

Growing

Babies and children with a 6q26 or 6q27 deletion can be tall, medium or short for their age. No child known to Unique was extremely small, most were of normal height and one or two were very tall. One youth with an interstitial 6q26 deletion is expected to reach 194 cm (6’5”) as an adult. Unique families mentioned that their child was lean or relatively lean for their height. In the medical literature, just one child was diagnosed with failure to thrive, where weight or weight gain is significantly less than other children’s of the same age and sex and one with growth delay (McLeod 1990; Stevenson 2004; Eash 2005; Mosca 2010; Unique).

Appearance

Doctors may notice in a baby what are known as ‘dysmorphic features’ which may or may not be obvious to a parent. Most of these are facial features of little or no importance to the baby.

Many babies have no ‘dysmorphic features’ at all, or only one or two. Some of the most common features are seen in many babies and children with a chromosome disorder, while others are more specific to a 6q deletion. The most common features seen in young babies with a 6q26 or a 6q27 deletion include an abnormal nasal bridge (deep, low, prominent), a tubular-shaped or broad nose, sometimes with a bulbous tip, ears that are set lower than the line of the eye,

may be tilted backwards and may occasionally stick out or be large or oddly crumpled; a 'fish-like' mouth, a 'tentled' or thin upper lip, a small lower jaw with possibly a pointed chin; widely spaced eyes that may be short, slant up- or downwards and sometimes have a tiny skinfold at the inner corner; and hooded eyelids. Unusual features noted in one or two children only include a tiny hole in one cheek in front of the ear, a high forehead, a large gap between the middle front teeth or crowded or wide-spaced teeth, full lips, a short neck and an asymmetrical or long, narrow face.

Features noticed among babies and children with a subtelomeric deletion include a tiny skinfold at the inner corner of the eyes; short eyes; a prominent groove between nose and upper lip; a high, broad or prominent nasal bridge; long eyelashes; large ears; a flat midface; narrowed or upslanting eyes; a short pointed nose; a broad mouth; a thin upper lip; a small lower jaw and chin; and asymmetry of the eyes or face. However, a few children had no typical facial features of note. Photographs showing a typical adult appearance can be seen in the medical literature in Striano 2006.

Hands and feet

Minor anomalies of the hands and feet are relatively common in children with chromosome disorders. These may just be cosmetic or they may make it harder for the child to use their hands or to walk. In terms of hands, babies in this group have been described with a range of quite trivial anomalies including narrow hands, long, thin fingers, shortened fingertips and short, sometimes broad finger joints and incurved fifth fingers as well as very flexible fingers and flat nail beds. As for feet, three babies grew into children with flat feet, two babies were born with club feet and two others had webbed toes; another child has big toes that curl up.

Children with orthopaedic problems that affect their mobility will be assessed and treatment tailored to the individual. Children with flat feet may be prescribed in-shoe supports or special footwear. Treatment for club foot aims to straighten the foot so that it can grow and develop normally. First-line treatment is non-surgical and may include manipulation, casting, taping, physiotherapy and splinting, followed by bracing to prevent relapse. Surgery and sometimes splinting are considered if non-surgical treatments are not completely successful. The foot position may relapse as the child grows and develops, making further surgery necessary. (Anderlid 2002; Eash 2005; Elia 2006; Mosca 2010; Unique)

Other features at birth

A [sacral dimple](#) (dimple or hole in the skin just above the crease between the buttocks) or similar defect near the base of the spine was seen in seven/27 Unique babies. The dimple may be shallow so you can see the base, but stools can collect there before your child is toilet trained, so keeping it clean and protected is all-important. A sacral pit may be deep and even connect to the

spinal canal. If there is any concern about this, your baby's spine will be imaged, usually with ultrasound or an MRI scan.

	How many children affected?
■ Abnormalities in brain structure or size	33/49
■ Seizures, generally well controlled	21/49
■ Heart condition	Occasional

Occasionally, the end of the spinal cord that is usually free within the spinal column becomes attached to one of the surrounding structures. This is called a tethered cord. A tethered cord can be put under tension as a child grows and moves and this can cause damage to the muscles and nerves that control the legs, feet, bowel and bladder. An MRI image will give a detailed 3-dimensional picture of the spine and spinal column. If necessary the cord can be surgically released so that it can hang freely. This spinal defect was seen in two Unique children. At least one baby was also born with a prominent coccyx, where the base of the spine bulges slightly outwards. In itself this is most likely to cause a little discomfort while sitting. One baby also had a fatty lump under the skin [lipoma] at the base of the spine and another had a small lipoma of the filum terminale, a fibrous strand that attaches the end of the spinal cord to the lower end of the vertebral column. (McLeod 1990; Lorda-Sanchez 2000; Rigon 2011; Unique)

Minor anomalies of the genitals and the bottom area are often seen in babies with a chromosome disorder, especially boys. In this group, the rate was low. Three out of 25 boys either had very small testicles or hypospadias, where the hole normally situated at the end of the penis is on the underside instead. Hypospadias can be surgically repaired using skin from the foreskin. (Elia 2006; Unique)

Medical concerns

There are great differences between individual children and adults with deletions from 6q26 and 6q27. Some people are completely healthy, while others have medical concerns.

■ Head and brain

A baby or child with a 6q26 or 6q27 deletion is likely to have imaging of the brain because in many cases - though not all - unusual structures have been found. There are two typical anomalies associated with a terminal 6q deletion. The first is colpocephaly, a brain anomaly where the rear portion of the fluid-filled ventricles of the brain is larger than normal. The second is a disorder of the band of nerve fibres that connects the two hemispheres of the brain (the corpus

callosum) (Striano 2006). The corpus callosum may be incomplete, abnormally formed, thin or it may be missing; in some children it is unaffected. What any unusual formations may imply for an individual child is not always clear but your child's doctors will explain the findings for your child.

Around one in four babies has a small head (microcephaly) and this may persist into adulthood. This judgement may be absolute or relative to the size of the rest of the body. Some children also have an unusually shaped head but in this group, no child needed surgery to release the plates of the skull to allow the brain to grow to a more normal shape.

Other anomalies have been found, including an increase in size of the ventricles, in some cases requiring drainage through a temporary or long-term shunt; an unusual shape to the ventricles; and polymicrogyria (an abnormality in the way the surface of the brain has developed resulting in too many folds that are smaller than normal in at least one region of the brain); a cerebellar cyst (a fluid-filled sac in the cerebellum, at the back and base of the brain); a small cerebellum; periventricular nodular heterotopias, where groups of brain cells are found in the wrong place, along the ventricles; an enlarged cisterna magna (the space beneath the arachnoid (middle meninges) that acts as a reservoir for cerebrospinal fluid); and broadened occipital horns (one of the three horns of the lateral ventricles, extending into the occipital lobe). Again, the implications of these unusual structures are not always immediately apparent, but a paediatric neurologist or your child's paediatrician is best placed to explain what they are likely to mean for your child. (Lorda-Sanchez 2000; Anderlid 2002; Stevenson 2004; Eash 2005; Bertini 2006; Elia 2006; Rooms 2006; Striano 2006; Mosca 2010; Rigon 2011; Unique)

■ Seizures

Around half of people including adults and children are known to have had seizures. Seizures of various types started between four months and four years of age. They were generally well controlled with conventional anti-epileptic medication, although one family tried homeopathic treatments alongside conventional medicine and in other cases children either outgrew their seizures or were managed without treatment. Due to this high frequency, it is recommended that babies and children with a subtelomeric 6q deletion have an electroencephalogram (EEG, recording of electrical activity in the brain) as well as imaging of the brain. There is some evidence that children with an epilepsy pattern that originates from the parietal-occipital lobes (at the back of the head) have a similar brain formation, including maldevelopment of the corpus callosum and the ventricles (colpocephaly) (Striano 2006). However, a 17 year old girl with other abnormal findings on brain imaging has had no seizures (Rigon 2011).

■ Heart

The great majority of babies had healthy, normal hearts. One baby was born with a hole between the upper chambers of the heart (atrial septal defect/ASD). Treatment for an ASD depends on the type of defect, whether it closes spontaneously and its size. Treatment can include medical management, taking medications to help the heart to work better, control of potential infection to the inner surfaces of the heart and surgical repair with stitches or a special patch. Another child had both an ASD and a hole between the lower pumping chambers of the heart (ventricular septal defect/VSD). In one baby the heart was on the right side of the body instead of the left (dextrocardia); if the heart is normally formed, a child with dextrocardia needs no medication or surgery. Two children were found to have a bicuspid aortic valve. This valve that regulates blood flow from the left ventricle into the aorta normally has three flaps or valves, but a bicuspid valve has only two. In one baby with a subtelomeric deletion, a heart condition was found at birth but its nature is not known (McLeod 1990; Stevenson 2004; Eash 2005; Unique).

■ Other concerns

Other conditions affected only individual children and might not have been caused by the 6q deletion. These included Meckel's diverticulum. This is a small pouch in the wall of the intestine near the junction of the small and large intestine. The pouch is a remnant of tissue from life before birth and is made of the same sort of tissue as is found in the stomach and pancreas. Most people do not have any symptoms or problems but in some cases the tissue produces acid which can create an ulcer within the intestine. If symptoms develop, the diverticulum can be removed with a surgical operation. After surgery children usually thrive with no long-term gastrointestinal problems.

Two babies had an inguinal hernia (in the groin), in one of them repaired at the age of three months. One baby was born with a channel connecting the windpipe with the food passage (tracheo-oesophageal fistula) and unspecified chest anomalies. A tracheo-oesophageal fistula will be repaired surgically. Another baby was born with the rectum placed far forward, requiring surgical correction.

One child developed a blood clot that obstructed the spleen.

Two children had features of Ehlers-Danlos syndrome, with very elastic, velvety thin skin, fragile tissues and unusually flexible joints, so walking was unstable and the knees flexed backwards.

Two children had a lipoma [small fatty lump] near the spine, suggesting that children with a subtelomeric 6q deletion should have spinal imaging (Flórez 2000; Anderlid 2002; Stevenson 2004; Eash 2005; Striano 2006; Mosca 2010; Rigon 2011; Unique).

■ Outlook

The outlook for any child is determined largely by their clinical problems. None of the babies or children in this group is known to have died in childhood and this is probably a reflection of their relatively low rate of major clinical problems aside from seizures.

■ Hearing

There have been no reports of long-term hearing impairment in this group, although some children have experienced the short-term fluctuating hearing loss caused by a build-up of fluid in the middle ear, usually associated with frequent ear infections.

■ Eyesight

Your child may be offered a detailed ophthalmological examination during which the retina at the back of the eye will be visualised because of a reported association between 6q deletions and abnormalities of the retina. However, in this group only one child was described as having an abnormal retina. The most common eyesight problem was strabismus (squint), corrected in one case with botulinum treatment and in others with patching, exercises and where needed conventional surgery. One child had a coloboma (developmental defect) in one eye; another had serious visual processing problems without eyesight abnormalities. A teenager was noted to be developing a cataract and kept under annual review (McLeod 1990; Eash 2005 ; Elia 2006; Striano 2006; Unique).



Development

■ **Sitting, moving: gross motor skills**

Most children with a deletion of 6q26 or 6q27 can expect to develop rather more slowly than other children but the evidence is that they will eventually achieve their 'baby milestones'. In general, babies learned to hold their head steady between two and five months; to roll over between six and 18 months, were able to sit up by six to 13 months, were crawling or bottom-shuffling between 10 months and two and a half years and walking from 14 months. One child with a 6q27 deletion and unusually flexible joints was walking from 30 months but two further children did not walk until their fourth year. Generally flexible joints have been seen in other children and at least one adult and may contribute to the delay in walking and running (Elia 2006; Striano 2006; Mosca 2010). Once on their feet, some children may have problems with balance and have a tendency to stumble but this does not affect all.

Underlying most children's mobility problems was low muscle tone, which makes them feel floppy and some needed the support of special seating as babies and standers and walkers while learning to walk. Some benefited from using splints or supports to steady their joints or supportive footwear. However, individual children showed a mixed pattern of hypotonia and increased tone (hypertonia).

The outlook for older children looks good, with teenagers enjoying excellent mobility and walking, running, climbing, riding, playing ball games and swimming, although this may not be possible for all.

In order to make these achievements, most children have needed input from physiotherapy, starting in the first year of life and usually ongoing until school age. Outcomes have generally been excellent.

“ Excellent mobility but accident prone ” – age 14

■ **Using their hands: fine motor and coordination skills**

Hand and eye co-ordination skills such as holding a bottle and playing with small toys may not develop in line with gross motor skills. In some children this may be due in part to their unusually flexible joints. Overall, there appears to be fairly consistent mild to moderate delay in hand use and fine motor skills as there is in toilet training. This delay means that early intervention by occupational therapy to stimulate hand use is vital. Most children in Unique have had reasonable outcomes after starting occupational therapy in their first or second year.

Holding a cup appears to become possible for some children by around three years and by six they can handle cutlery but may remain clumsy. By the early school years, most children can undress and dress for the most part but may well still need help with fastenings and shoe laces. At school they tend to have persisting problems holding a pencil.

The late development of self help skills means that children achieve relative independence somewhat later than other children. Toilet training in the day-time appears to be achieved between two and five years, but some children will take longer than this and this may include children who have had tethered cord release. Age of toilet training for children with a simple sacral dimple does not appear to be affected.

■ Speech and communication

While some delay in the emergence of speech and language is to be expected, the extent of the delay is variable and probably reflects the level of cognitive ability, but appears in most children to be mild. The great majority of children do learn to speak although this may not be possible for all.

Most children have had the benefit of speech therapy starting between the ages of two and six years, with generally successful outcomes.

- A three-year-old speaks 10 to 15 words, enough to make himself understood and otherwise uses hand gestures. He seems to understand all the basic things he is told.
- A four-year-old communicates by signing and pointing; makes lots of vocal noises and babbles and understands much more than she can express.
- A five-year-old has been talking with meaning for a year and with intensive speech therapy support can now speak in two languages, using 4-5 word phrases with articles and verbs in the infinitive. He avoids prepositions and prepositional nouns as he knows he has difficulty with them.
- A seven-year-old holds conversations in which she uses multiple sentences. She occasionally mixes word order and has some articulation problems but her speech and language skills are delayed only by around 12 months.
- A 14-year-old is highly verbal with a superior vocabulary and a large gap between receptive and expressive language. When he tries, he is capable of very sophisticated concepts. His speech is at a normal to advanced level for his age. Until he was seven, he had difficulty with articulation.
- A 15-year-old communicates with speech in 2-3 word phrases; he occasionally stutters but his speech has improved over time.

■ Learning

Children are likely to need some support with their education. While predicting the level of support needed is not possible from the size of the chromosome deletion, it seems that most children will have a moderate, mild or borderline learning difficulty, perhaps with some areas of superior ability. In a 12-year-old with a subtelomeric deletion, IQ measurement was 78; in a 5-year-old, it was 69; a 33-year-old with persistent but well-controlled seizures had an IQ of 55. However some children have severe learning difficulties. Most children will experience problems with fine motor coordination and find handling a pencil difficult. Some children are also likely to have visual problems or problems with processing visual information and may learn best aurally. Families comment

that their children learn best when following a routine; in general they have a good, if uneven, memory. They succeed by learning by repetition, competing with their peers, being interested in the subject and by sheer determination. Children often start their education in a mainstream (regular) school, usually with learning support, and transfer to a special school usually for secondary education where their specific needs can be met more appropriately.

“ He loves a paintbrush but hates a pen or pencil ” - *age 5*

“ She has a good memory for social situations and is especially able at reading ” - *age 10*

“ He doesn't read much but can write short paragraphs and enjoys abstract drawing. His ability with video games is awesome ” - *age 14*

■ Behaviour

There is no evidence yet of a particular behavioural pattern associated with subtelomeric 6q deletions, although there is some slight evidence that some children may develop autistic features and one boy of 12 years has been described as anxious, with a conduct disorder and a tendency to self-mutilating behaviour. Twin boys were both described as hyperactive. Children's behaviour is modulated by their experiences as well as their perceptions, successes and frustrations. The snapshots that follow illustrate families' experiences at a variety of ages.

- She enjoys going for walk in her stroller, swinging, looking for animals, swimming, listening to music and watching DVDs. Overall she is generally happy. If she can't express what she wants or isn't happy she bangs her head - *age 4*

- Recently shown some challenging behaviour, restlessness and inappropriate friendliness - *age 6*

- Enjoys playing with other people, animals, to colour and draw; music, singing and dancing. Sociable and affectionate. Can get frustrated and has had input from a behavioural therapist. Takes risperidone (as tranquilliser) and is learning to stop and take deep breaths. Used to take imipramine (an antidepressant) and clonidine (a drug with sedative effects) to sleep but now sleeps easily and deeply without - *age 10*

- Makes an effort to fit in socially and has play dates and sleepovers with typically developing and learning disabled friends. Somewhat inflexible; we have learned to back off and keep stress low. Loves nature and animals; can be moody, likes to be left alone and can get overwhelmed when among more than a few peers. Responds to stress by getting upset. Needs direction; we also use sensory integration techniques. To help sleep and reduce anxiety, takes low-dose imipramine at night - *age 14*

- A very polite, well mannered boy; very little problem at all - *age 15*

■ Growing up

There is limited information on youngsters growing up but a youngster of 15 is being taught to drive and run the canteen at school. Puberty in two youths proceeded normally with mood swings the most obvious manifestation. At least four adults with a 6q27 deletion have children with the same deletion.

Why did the deletion occur?

Most 6q deletions occur out of the blue and on examination the parents have normal chromosomes. The genetic term for this is de novo (dn) (see page 4). Dn 6q26q27 deletions are caused by a mistake that occurs when the parents' sperm or egg cells are formed or else very shortly after conception, when a baby is made.

Occasionally, one parent is found to have a change in their own chromosomes at 6q26 or 6q27 that makes them much more likely to have a child with this type of deletion. A blood test to check the parents' chromosomes will show what the situation is. In four families, a 6q27 deletion has been passed down directly from either the mother or the father to one or more children (Kraus 2003; Rooms 2006; Unique).

In bands 6q26 and 6q27 there do not appear to be any particular hotspots or 'weak sites' where the chromosome is liable to break and re-join. This is one reason why there are individual differences between people with 6q26q27 deletions - they have different break points in the chromosome, with slightly larger or smaller missing sections.

Whether the deletion is inherited or dn, what is certain is that as a parent there is nothing you did to cause it and nothing you could have done would have prevented it from occurring in your child. No environmental, dietary or lifestyle factors are known to cause these chromosome changes. No one is to blame when this occurs and nobody is at fault.

Can it happen again?

The possibility of having another pregnancy with a 6q deletion depends on the parents' chromosomes. If both parents have normal chromosomes, the 6q deletion is very unlikely to happen again. If a blood test shows that either parent has a chromosome change involving 6q, the possibility is increased of having other pregnancies with chromosome changes. Once a family chromosome change is known, a test in any future pregnancy can find out whether the baby's chromosomes are affected. A genetic specialist can give you more guidance.

When one parent has the same 6q27 deletion as the child, the likelihood of having another child with a 6q27 deletion is likely to be as high as 50 per cent. Although the only cases we know about so far involve 6q27 it is also theoretically possible for a small 6q26 microdeletion to be passed down from parent to child.

Will my child with a 6q26 or 6q27 deletion have similarly affected children?

Adults with 6q deletions may form close relationships and want to have children. It is not yet known for certain whether the deletion affects fertility but in some cases it is possible that fertility will be normal. There are families with 6q27 deletions passed down through the generations. In each pregnancy, someone with the deletion is likely to have a possibility of passing it on that could be as high as 50 per cent and a 50 per cent possibility of having a child without the deletion. Their ability to look after a child is very likely to be closely related to their own degree of learning difficulty.

Support and Information



Understanding Chromosome & Gene Disorders

Rare Chromosome Disorder Support Group

The Stables, Station Road West, Oxted, Surrey RH8 9EE, UK

Tel/ +44(0)1883 723356

info@rarechromo.org | www.rarechromo.org

Join Unique for family links, information and support

Unique is a charity without government funding, existing entirely on donations and grants. If you are able to support our work in any way, however small, please make a donation via our website at:

www.rarechromo.org/donate

Please help us to help you!

Chromosome 6 research project

The C6 project works with families to collect detailed information with the aim of linking specific disease characteristics with specific regions of chromosome 6.

<https://www.chromosome6.org/>

Facebook page for chromosome 6

www.facebook.com/groups/chromosome6

Unique lists other organisations' message boards and websites in order to be helpful to families looking for information and support. This does not imply that we endorse their content or have any responsibility for it.

This information guide is not a substitute for personal medical advice. Families should consult a medically qualified clinician in all matters relating to genetic diagnosis, management and health. Information on genetic changes is a very fast-moving field and while the information in this guide is believed to be the best available at the time of publication, some facts may later change. Unique does its best to keep abreast of changing information and to review its published guides as needed. The guide was compiled by Unique and reviewed by Professor Robert Hopkin, Division of Human Genetics, Cincinnati Children's Hospital Medical Center, Cincinnati, Ohio, USA and by Professor Maj Hultén BSc, PhD, MD, FRCPath, Professor of Reproductive Genetics, University of Warwick, UK, 2007. Revised June 2011. (PM)

Copyright © Unique 2018